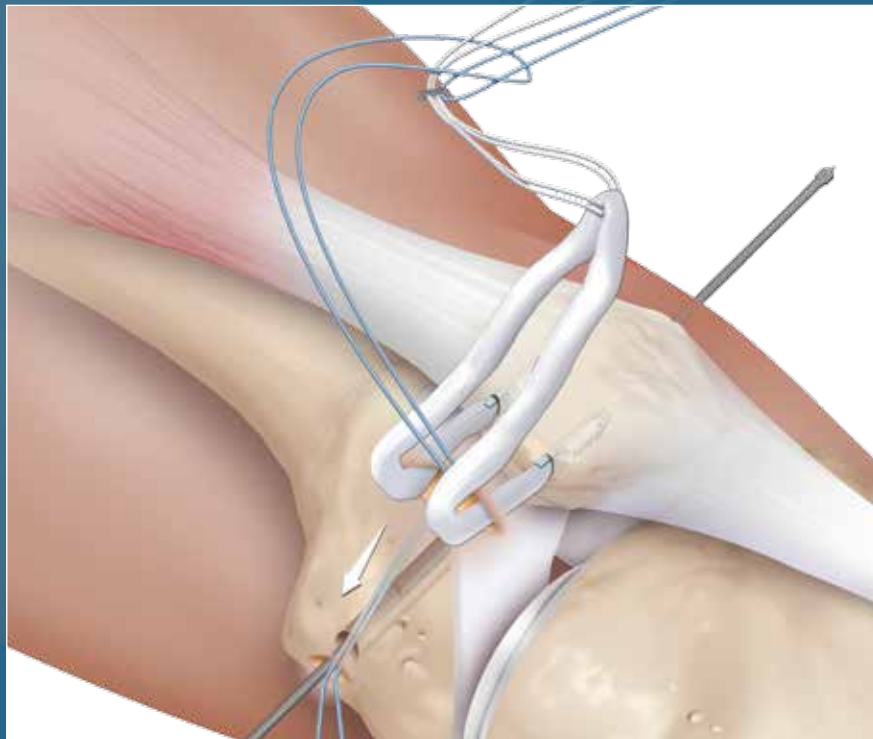




MPFL with ACL TightRope® Implant and  
3.5 mm SwiveLock® Anchor

Surgical Technique



MPFL with ACL TightRope

The medial patellofemoral complex, consisting of the medial patellofemoral ligament (MPFL) and the medial patellotibial ligament, is the main passive stabilizer of the patellofemoral joint. Since it has been shown that rupture of the MPFL is the main pathological consequence of patellar dislocation<sup>2</sup> and biomechanical studies have demonstrated that the MPFL is the main passive restraint against patellofemoral instability (PFI) and lateral patellar displacement, reconstruction of the MPFL has become a widely accepted technique for restoration of patellofemoral stability. Therefore, numerous techniques for reconstruction of the medial patellofemoral complex have been described with promising clinical results<sup>3</sup>. However, since it is known that a nonanatomic reconstruction of the MPFL can lead to nonphysiologic patellofemoral loads and kinematics<sup>1</sup>, the goal of surgical intervention must be an anatomic reconstruction. There have been multiple studies to evaluate the femoral insertion of the MPFL. Based on these anatomic<sup>1</sup>, biomechanical<sup>6</sup> and radiologic<sup>5</sup> findings, it is now possible to avoid the complications of increased patellofemoral pressure that is associated with nonanatomic (too anterior/proximal<sup>1</sup>) fixation of the graft.

The Anatomic Double Bundle MPFL Reconstruction technique replicates the native shape of the MPFL and provides outstanding flexion and extension. The Double Bundle technique also effectively limits rotation throughout the ROM, minimizing postoperative instability. The technique, if accomplished directly and anatomically, may also provide for more aggressive rehabilitation protocols and earlier return to activity<sup>4</sup>.

As mentioned above, an important determinant of a successful outcome of MPFL reconstruction is the proper position of the femoral fixation of the graft, and our technique incorporates the use of a femoral template to ensure proper placement of the graft in the femur. This position provides a static fixation point that equalizes the tension across the graft in flexion and extension, thus minimizing the stresses across the patellofemoral joint.

## PATHOMORPHOLOGY OF PFI OVERVIEW

The pathomorphology of PFI is dependent on different static and passive factors, such as alignment of the lower limb, dysplasia of the trochlea, and functionality of the MPFL. The patella is primarily stabilized by the medial patellofemoral complex from full extension to approximately 20° of flexion, and has no bony guidance, thus forcing the MPFL complex to bear the load of restraint against the lateralizing vector of the quadriceps muscle.

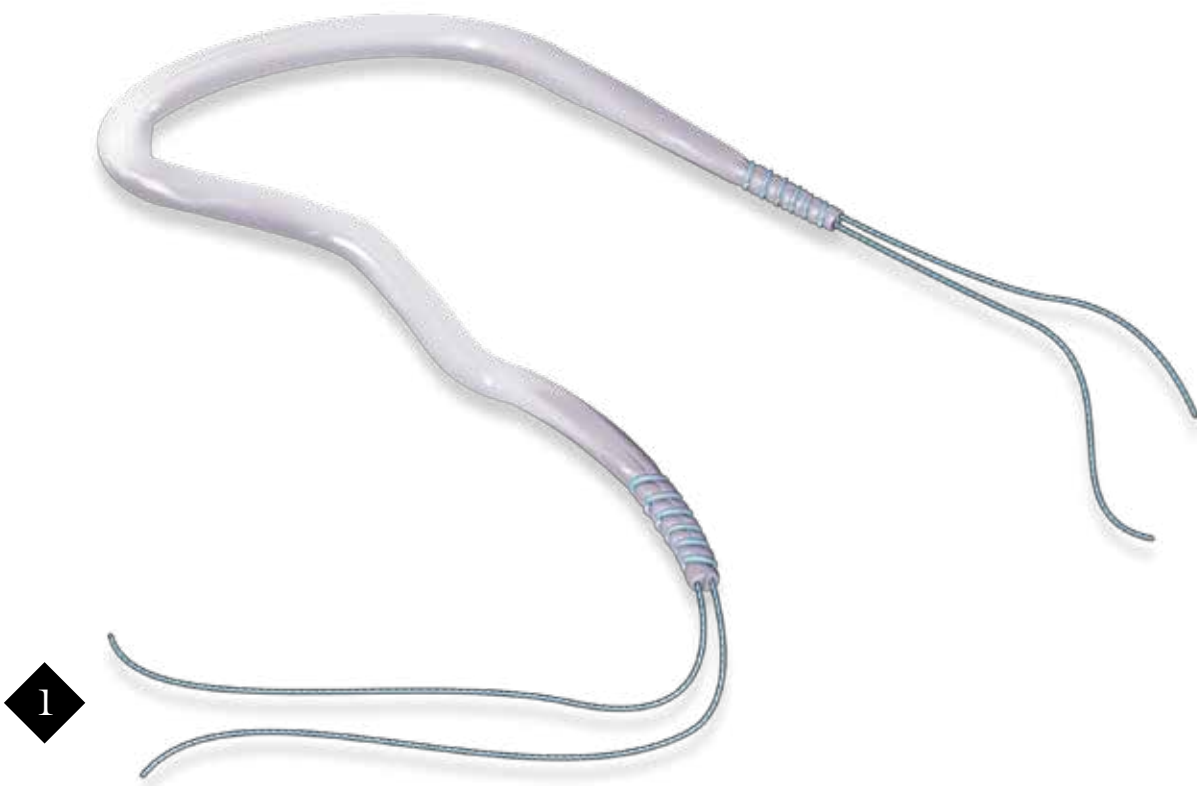
At about 20° of flexion the patella should engage into the trochlear groove, where the lateral trochlear facet is providing the static stabilization against patellar lateralization. The trochlea provides stability up to 60-70° of flexion, where the patella begins engaging into the notch. In cases of trochlear dysplasia, the patella cannot be guided properly and dislocation of the patella can occur more easily.

Very seldom, there are cases where the patella does not engage the notch in greater than 70° of flexion, and instability occurs. This can occur in cases of a valgus deformity or internal rotation of the distal femur, where the trochlear groove and the notch are positioned medially and the patella cannot engage. Chronic patellar dislocation is often seen in these cases with the patella tracking on the lateral condyle during the entire range of motion. In these cases, a realignment procedure should be considered.

## INDICATION FOR MPFL RECONSTRUCTION

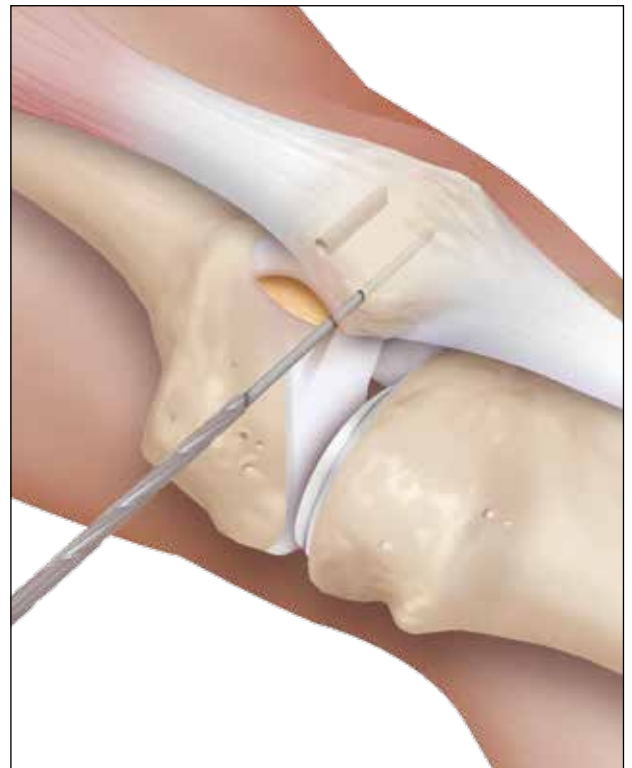
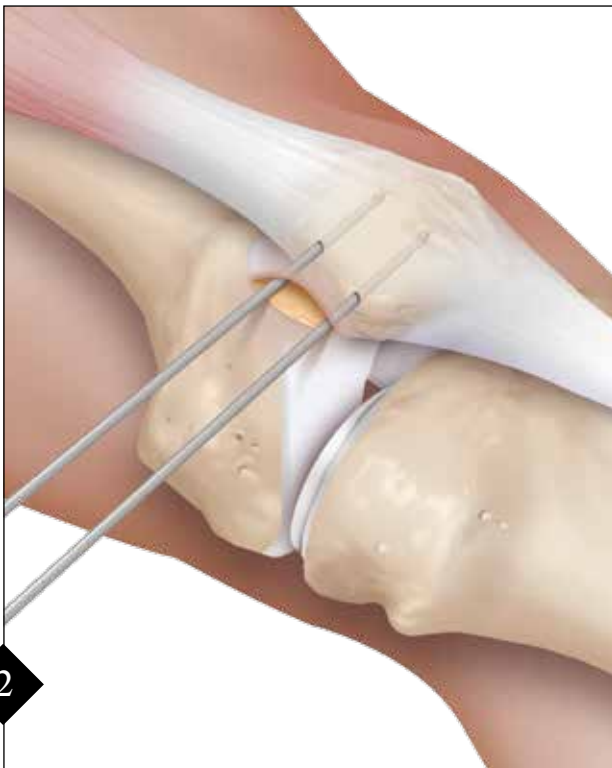Since most cases of patellar instability occur in extension or slight flexion, with a slight underlying trochlear dysplasia, the majority can be treated with a reconstruction of the MPFL. The MPFL is ruptured in almost all cases after an acute patellar dislocation and is additionally weakened in cases of congenital trochlear dysplasia, since the patella tracks improperly from early childhood. The additional stresses and tension on the medial soft tissue complex from this maltracking can lead to an underdeveloped or insufficient MPFL and subsequent instability. Also, in cases with a PFI in deeper flexion, reconstruction of the MPFL should be considered as a concomitant procedure to provide stability in extension.

## GRAFT SELECTION



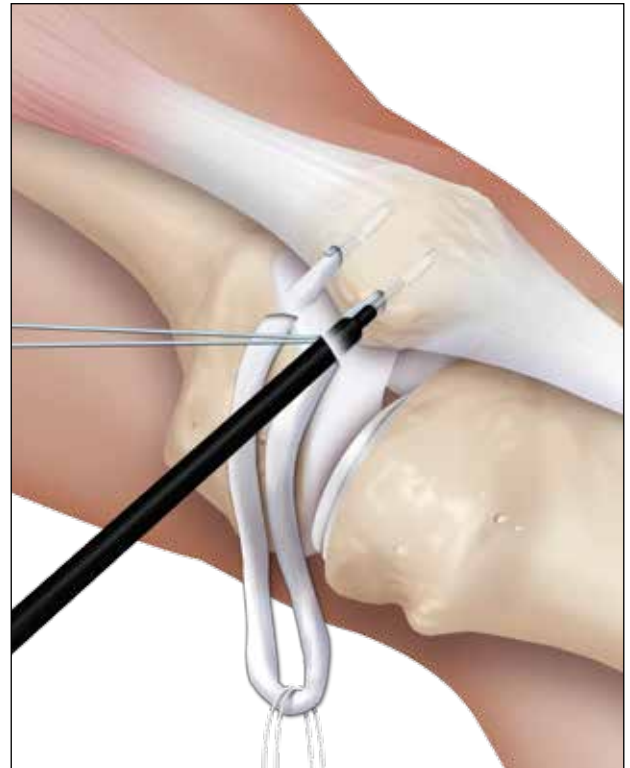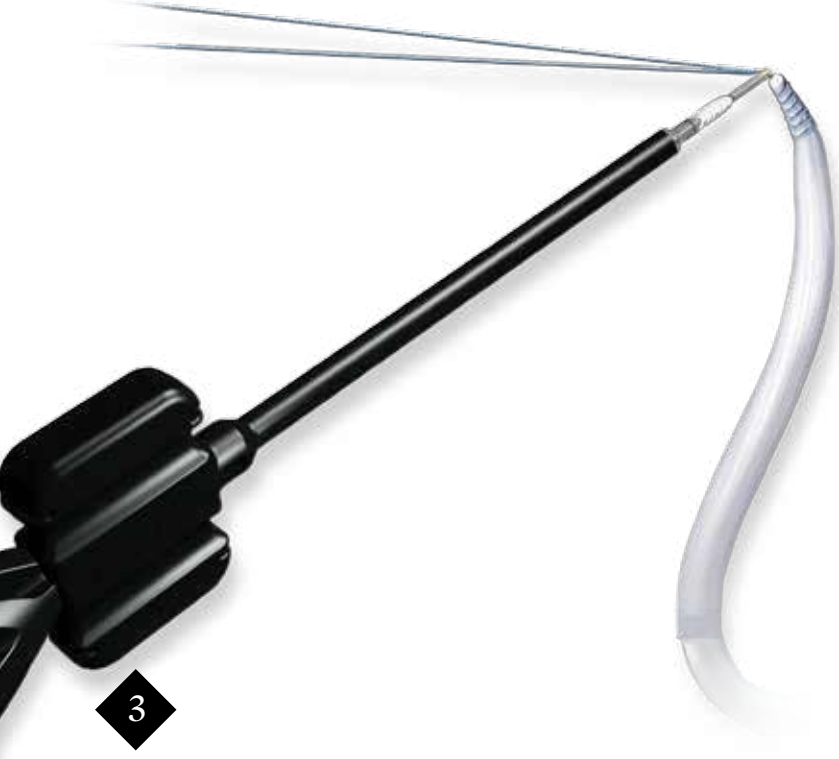
A gracilis autograft is used, as the size and strength has been shown to be sufficient for MPFL reconstruction (approximately 4 mm in diameter)<sup>7</sup>. Minimum graft length is 18 cm, whipstitched 10 mm at each end with a 2-0 FiberWire® suture. The graft should be tapered at each end to facilitate insertion of the graft into the patella.

## PREPARATION OF THE PATELLA



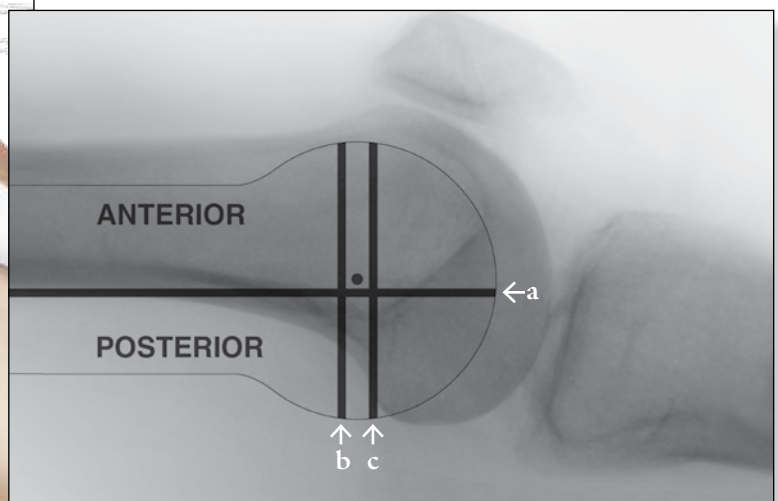
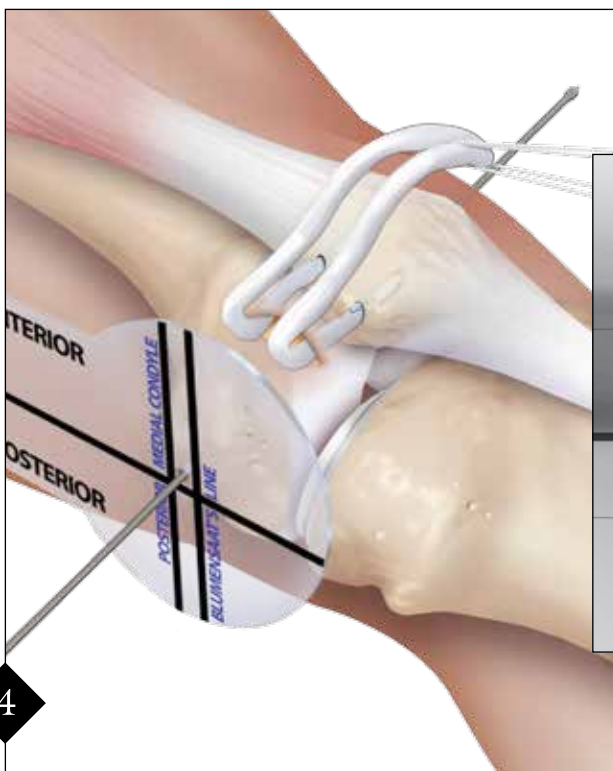
Palpate the medial patellar border and make a 2 cm skin incision from the superomedial corner, extending to the center of the medial edge of the patella. Dissect down and expose the medial edge of the patella. Under fluoroscopic guidance, at a point 3 mm distal to the proximomedial corner of the patella, drill a 1.1 mm drill tip Guide Pin in a transverse fashion across the patella to a minimum depth of 20 mm. Place a second 1.1 mm Guide Pin 15-20 mm distal and parallel to the first one. Overdrill the two Guide Pins with a 3.5 mm cannulated reamer to a depth of 18 mm. **Note: Remove both Guide Pins after overreaming is complete.**

## GRAFT FIXATION TO THE PATELLA



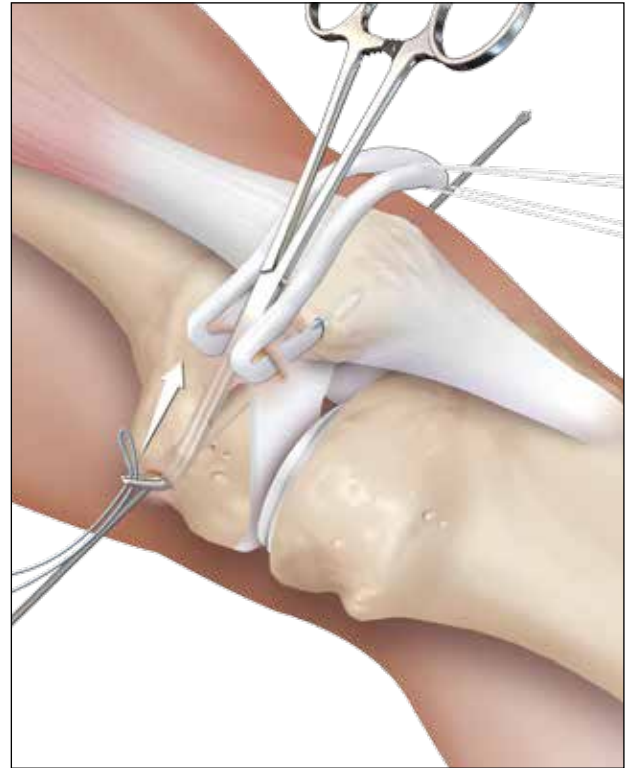
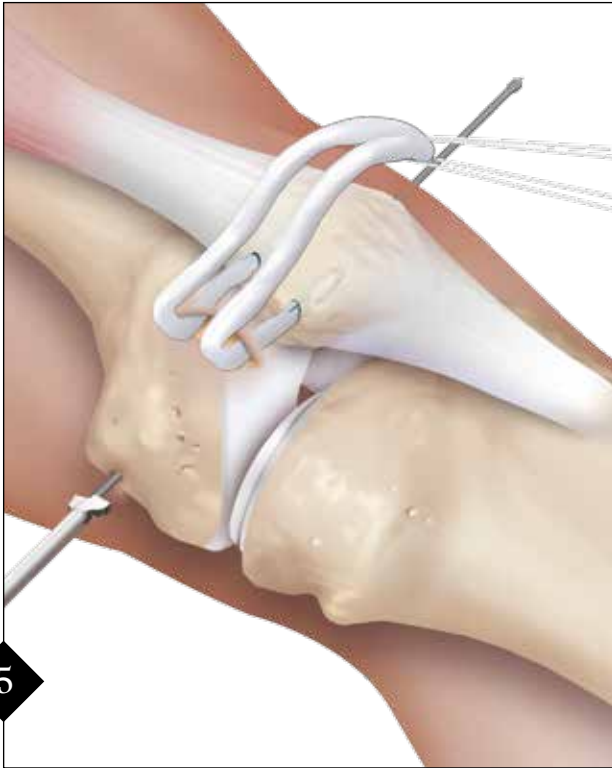
3 Pass the tails of one graft end through the eyelet of the first 3.5 mm BioComposite™ anchor and push the graft/anchor into the proximal drill hole until the eyelet is fully seated. Maintain tension on the suture limbs and screw the BioComposite anchor into the patella. After removal of the driver, the suture should be removed or tied to the graft sutures to reinforce the fixation. *Before inserting the second SwiveLock® anchor, loop the TightRope® implant (AR-1588T) over the graft.* Then, repeat the SwiveLock insertion procedure with the second graft end.

## PREPARATION OF FEMORAL INSERTION

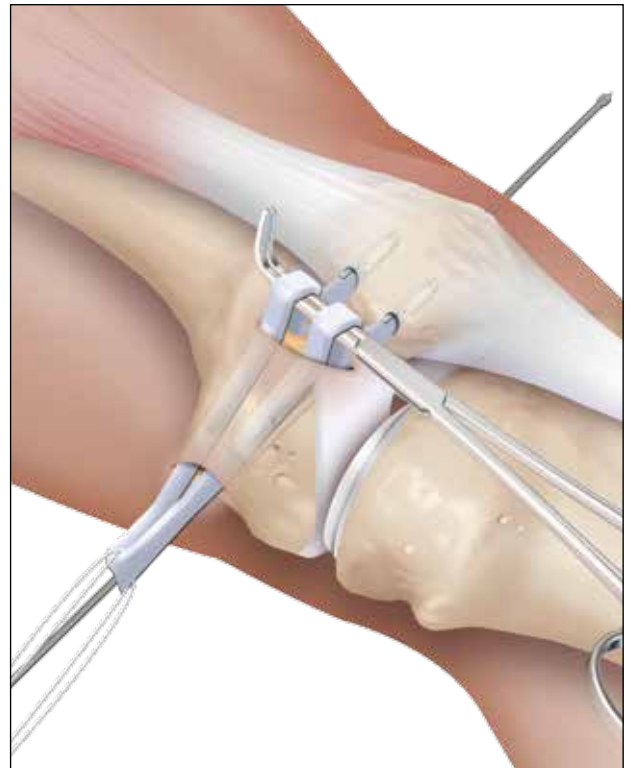
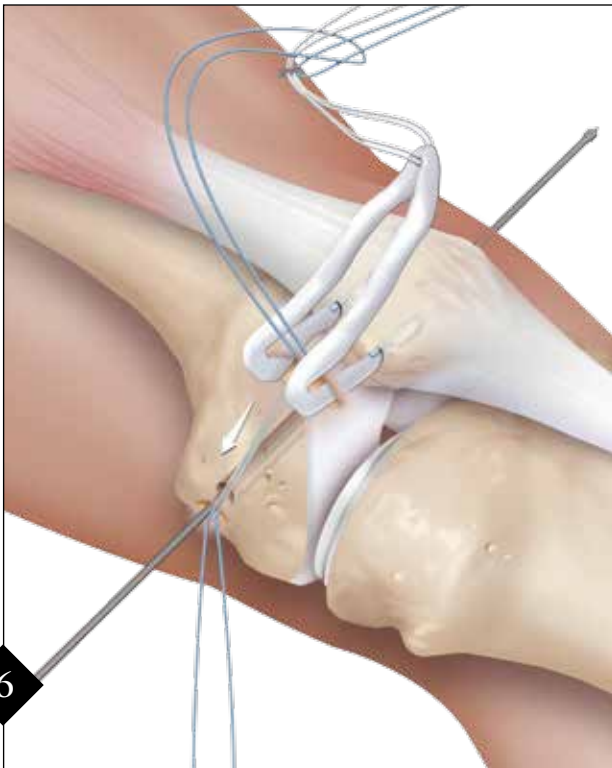


4 The proper position of the femoral insertion of the MPFL is very important to maintain proper biomechanics of the patellofemoral joint throughout the entire range-of-motion (ROM). The use of the MPFL template can help establish the position of the Guide Pin. The insertion point is approximately (a) 1 mm anterior to the posterior cortex extension line, (b) 2.5 mm distal to the posterior articular border of the medial femoral condyle, and (c) proximal to the level of the posterior point of Blumensaat's line. The template is placed on the area of the medial epicondyle on the distal femur and, under fluoroscopic guidance, a 4 mm spade tipped Drill Pin (AR-1595TC) is drilled across the femur and out through the lateral epicondyle. *Note the intraosseous length and mark that distance on the TightRope implant.* The Pin should be aimed slightly proximal and anterior to avoid the intercondylar notch.

## PREPARATION OF THE MEDIAL PATELLOFEMORAL LAYER

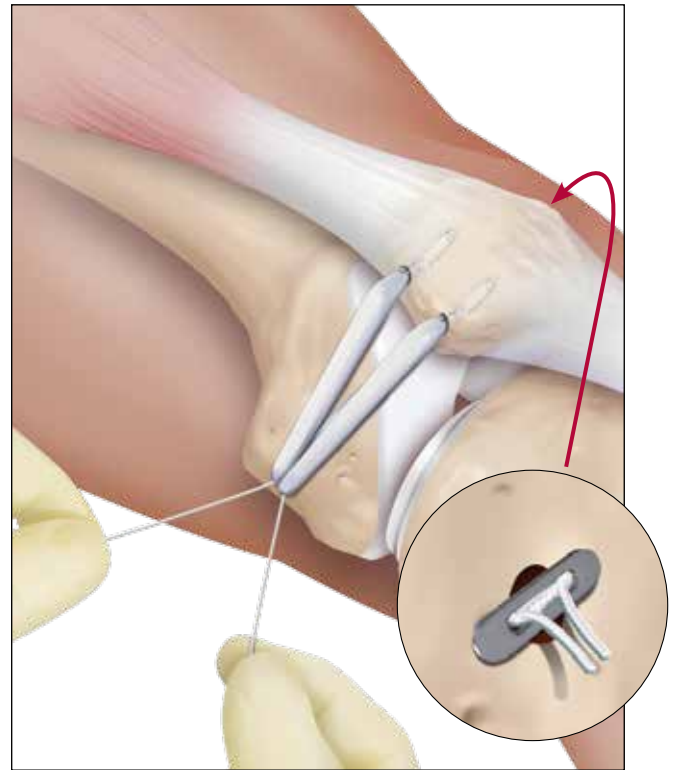
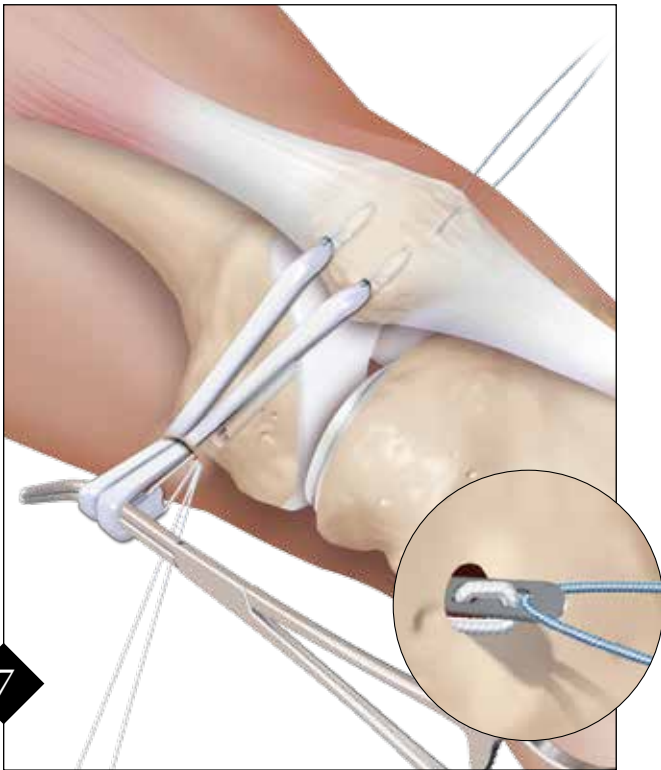


Drill to the far cortex. Maintain the 4 mm spade tipped pin in the femur, as it will be used to pass the TightRope® sutures and graft into the femur. Identify the space between the vastus medialis and the capsule, and bluntly dissect towards the femoral insertion area with a scissor, leaving the capsule intact. A right angle clamp is inserted into the prepared layer down to the medial epicondyle and the tip of the clamp is turned towards the skin. Make a 1 cm longitudinal incision and, using the clamp, pass a looped #2 FiberWire® suture back to the patellar insertion area. *Note: Before drilling, the isometry of the MPFL may be provisionally evaluated. Pass the graft to the femoral incision. Wrap it around the pin, maintaining adequate tension on the graft and cycling the knee through the ROM. If isometry is not adequate, change the pin location before drilling with the 6 mm reamer.*



Loop the TightRope sutures through the #2 FiberWire and pass the graft from the patellar origin to the insertion point at the medial femoral epicondyle. It is very important to maintain equal tension on both graft bundles during this step to ensure proper biomechanics of the patellofemoral joint. Deliver the TightRope sutures out of the medial incision, and, with equal tension on both graft bundles, pull the graft down to the medial epicondyle.

## FEMORAL GRAFT PASSAGE AND FIXATION



Loop the TightRope® passing sutures (blue) into the eyelet of the spade pin and deliver the suture tails out of the lateral femur prior to the graft entering the femoral socket. Using a clamp as a pulley, pretension the graft and insert it into the socket with equal tension on both graft bundles as the TightRope is pulled out the lateral side. Maintain tension on graft until the TightRope Button is flipped on the cortical bone on the lateral side (*inset*). **Note: If the button cannot flip because the sutures are too short, or excessive force must be used to flip the button, lengthen the TightRope sutures manually before passing and filling the button.** Manually fixate the lateral patellar facet flush with the lateral femoral condyle with the knee at 30° of flexion.

Final fixation can be accomplished by pulling the TightRope's tightening sutures (white) on the medial side, alternating tension on each strand 2 cm at a time.

*It is crucial that the tensioning sutures are not overtightened while holding the patella in the middle of the trochlear. The TightRope cannot be loosened. Overtightening of the TightRope could result in the patella being overconstrained to the medial side.*

*Note: Evaluate the tracking and tension of the patella throughout the knee ROM. If any adjustments need to be made, the TightRope can be cut out. Tensioning adjustments can be made, and a BTB TightRope (AR-1588BTB) or BioComposite™ Interference Screw (AR-1360C) can be used to fixate the graft.*

## POSTOPERATIVE CONSIDERATIONS

A postoperative brace locked at 0°-90° of flexion should be worn for a period of 6 weeks. Weight-bearing is limited to partial weight-bearing crutch ambulation until wound healing is complete and at that point can be increased according to the pain tolerance of the patient. Full ROM is allowed after 6 weeks with light jogging or cycling. The patient can resume full activity at 12 weeks.

## ORDERING INFORMATION

### MPFL Convenience Pack (AR-1360CST-CP) includes:

MPFL Template (a)

BioComposite SwiveLock, 3.5 mm, qty. 2

ACL TightRope

ACL TightRope Drill Pin, closed eyelet, spade tip, 4 mm


Guide Pin, drill tip, 1.1 mm, qty. 2

Low Profile Reamer, 6 mm

Cannulated Drill, 3.5 mm

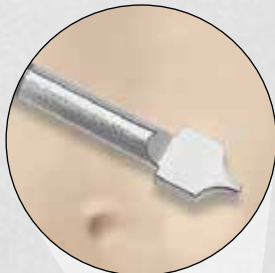#### **References:**

1. Amis AA, Firer P, Mountney J, Senavongse W, Thomas NP, *Anatomy and Biomechanics of the Medial Patellofemoral Ligament*, Knee 10: 215-220, 2003.
2. Desio SM, Burks RT, Bachus KN, *Soft Tissue Restraints to Lateral Patellar Translation in the Human Knee*, Am J Sports Med 26: 59-65, 1998.
3. Nomura E, Inoue M, *Surgical Technique and Rationale for Medial Patellofemoral Ligament Reconstruction for Recurrent Patellar Dislocation*, Arthroscopy 19, issue 5: 47e, 2003.
4. Schottle PB, Hensler D, Imhoff AB, *Anatomical Double-Bundle MPFL Reconstruction with an Aperture Fixation*, Knee Surg Sports Traumatol Arthroscopy (epub ahead of print), 2009.
5. Schottle PB, Schmeling A, Rosenstiel N, Weiler A, *Radiographic Landmarks For Femoral Tunnel Placement In Medial Patellofemoral Ligament Reconstruction*, Am J Sports Med 35: 801-804, 2007.
6. Steensen RN, Dopirak RM, McDonald WG, III, *The Anatomy and Isometry of the Medial Patellofemoral Ligament: Implications for Reconstruction*, Am J Sports Med 32: 1509-1513, 2004.
7. Philip Schöttle, Arno Schmeling, Jose Romero, Andreas Weiler, *Anatomical reconstruction of the medial patellofemoral ligament using a free gracilis autograft*, Arch Orthop Trauma Surg (2009) 129:305-309.



a

Spade Tip



*This description of technique is provided as an educational tool and clinical aid to assist properly licensed medical professionals in the usage of specific Arthrex products. As part of this professional usage, the medical professional must use their professional judgment in making any final determinations in product usage and technique. In doing so, the medical professional should rely on their own training and experience and should conduct a thorough review of pertinent medical literature and the product's Directions For Use.*



[www.arthrex.com](http://www.arthrex.com)

... up-to-date technology  
just a click away

View U.S. patent information at [www.arthrex.com/corporate/virtual-patent-marking](http://www.arthrex.com/corporate/virtual-patent-marking)

©2016, Arthrex Inc. All rights reserved. LTI-0123-EN\_C