

SCOPE THIS OUT

..... A Technical Pearls Newsletter for Orthopedists

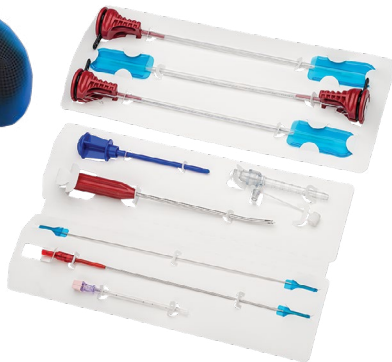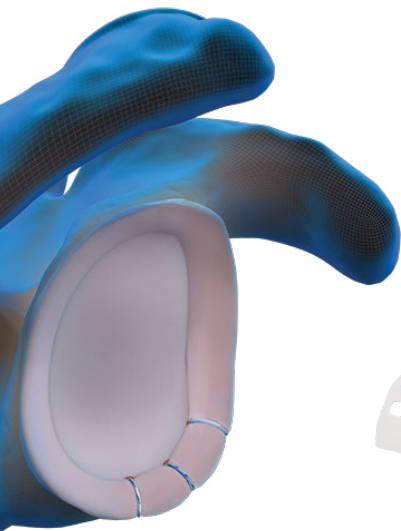
Knotless 1.8 FiberTak® Implant System for Shoulder Instability Repair

Knotless FiberTak soft anchors are the market-leading solution for shoulder instability repairs. The new Knotless 1.8 FiberTak Implant System integrates the latest innovations in instrumentation and suture development into one convenient package. Finding the best placement for the implants has never been easier, thanks to the included percutaneous cannula and curved drill guide instrumentation.

The implants feature a tensionable, knotless mechanism created using a shuttle suture for a low-profile, knotless repair. The system includes three, small Knotless 1.8 FiberTak implants, each with a uniquely designed tapered-tail repair suture for smooth shuttling. Each repair suture is color-coded for ease of suture management. Due to their small 1.8 mm footprint, additional anchors may be added to address larger glenohumeral soft-tissue injuries.



Learn more

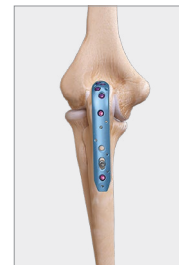
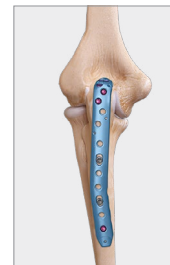
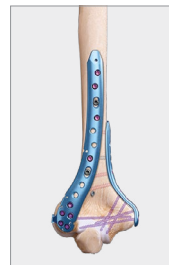
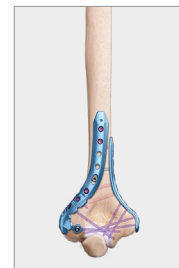
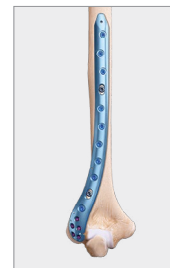
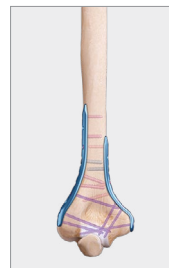Arthrex Elbow Plating System

The Arthrex Elbow Plating System is a comprehensive distal humerus and olecranon plating portfolio that rounds out the Arthrex Trauma portfolio. Alongside a platform of soft-tissue anchors, FiberTape® cerclage, and biologics, the Arthrex elbow portfolio is the most complete on the market.

Features and Benefits

- 180° and 90° distal humerus plating constructs
- Extra-articular distal humerus plate lengths up to 294 mm
- Dorsal olecranon and olecranon osteotomy plates
- All plates are compatible with KreuLock™ locking compression screws
- All plate screw holes can accommodate 2.7 or 3.5 mm shaft hybrid screws
- Removable screw tabs allow for extra fixation and can be removed if desired

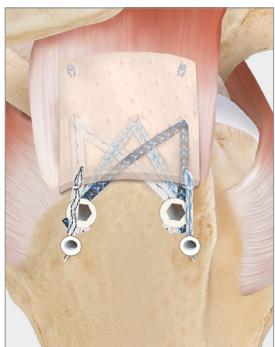


Upper Extremities

FiberStitch™ RC Simple: Quicker and Easier Than Ever!

The FiberStitch RC has been a valuable addition to the CuffMend™ rotator cuff augmentation procedure, providing quick, secure, all-suture fixation of the graft to the tendon. A number of surgeons have adopted the technique of “sandwiching” the graft to the tendon by placing one FiberStitch implant underneath the tendon and another on top of the graft. This method creates a simple and efficient stitch, providing a quicker option for medial fixation of the ArthroFlex® dermal allograft.

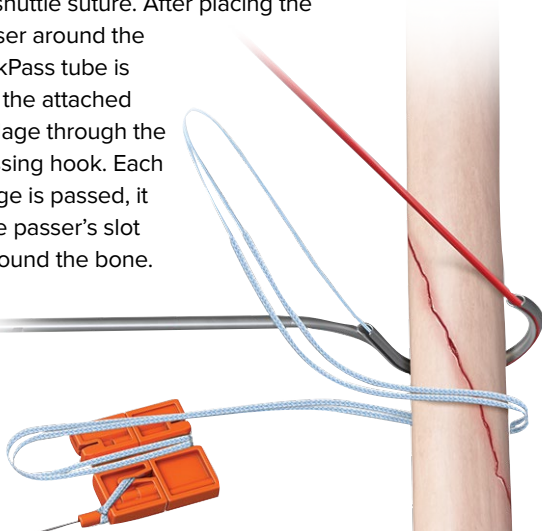
Based on feedback from surgeons, we have developed a new version of FiberStitch RC that has been optimized for this technique. The new FiberStitch RC makes it easy to deploy a single implant under the cuff, then remove the inserter, leaving the second implant above the graft for quick tensioning of the construct.



ArthroFlex is a registered trademark of LifeNet Health.

Introducing the QuickPass™ FiberTape® Cerclage System

The QuickPass FiberTape Cerclage System is the latest addition to the FiberTape Cerclage System and introduces a faster, more efficient way to pass FiberTape cerclage. It includes the FiberTape cerclage with red QuickPass tube and the cannulated, slotted QuickPass passers. The QuickPass tube used in conjunction with the cannulated, slotted passers enable the FiberTape cerclage to be passed around the bone twice without the need for a separate shuttle suture. After placing the QuickPass passer around the bone, the QuickPass tube is used to deliver the attached FiberTape cerclage through the cannulated passing hook. Each time the cerclage is passed, it slides out of the passer's slot and remains around the bone.




ElbowLOC® Arm Positioning System

The ElbowLOC arm positioning system is an upper-extremity positioning device designed specifically for surgeries from the midhumerus to the fingers, all within one self-contained sterile system. The system enables traction across the elbow or wrist and unhindered intraoperative elbow motion and forearm manipulation, depending on the fracture and reduction needed.

The ElbowLOC system features:

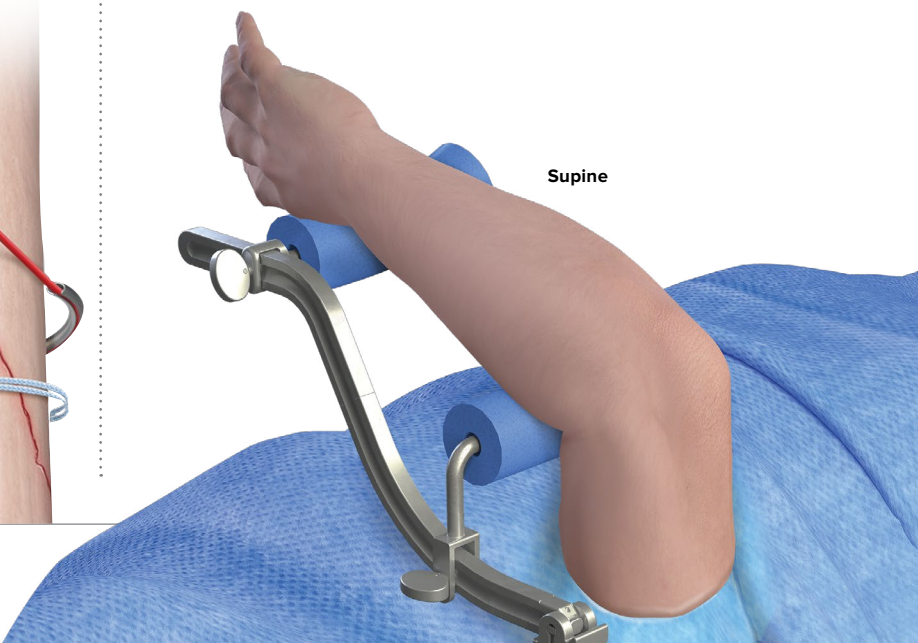- An entire four-positioner system contained in one autoclavable case
- Supine, lateral, or supine suspended positioning for elbow surgery
- Rigid wrist tower fixation
- Applied sterile over drapes to standard OR table railing
- Sterile disposable field kits for elbow procedures
- Nylon double-finger traps for wrist surgery



Supine Suspended

Lateral Position

Wrist Tower



Supine

Knee & Hip

Atraumatic Joint Access With the SafeCut™ Capsulotomy Blade

The SafeCut capsulotomy blade is specifically designed to reduce the risk of iatrogenic damage to the acetabular labrum and cartilaginous surfaces of the hip. Incorporating a simple yet significant technological improvement, the blunt-tip SafeCut blade provides safer access when inserting the capsulotomy blade through a cannula and into the hip joint.

In conjunction with the FlushFit disposable cannula system, the SafeCut blade provides everything needed for atraumatic hip joint access.

Features and Benefits

- Solid, single-piece design
- Ideal for cutting through thick capsular tissue
- Straight and curved versions available
- Compatible with the FlushFit disposable cannula system



Learn more about the SafeCut blade [here](#).


Shoulder Arthroplasty

Augment Locking Reamers for the MGS and Unvers VaultLock® Glenoid Systems

These newly redesigned locking reamers feature a “twist-and-lock” mechanism that aims to provide a more secure fit to the associated redesigned reamer drive shaft, addressing the issue of existing augment reamers inopportunistically disconnecting from their drive shafts intraoperatively.

When fully assembled and positioned over the guidewire, flanges incorporated into the reamer shaft prevent it from unthreading, thus preventing disassociation.

Additionally, the reamer heads for VaultLock glenoid preparation have been redesigned to leverage the benefits of a Nautilus shape—reducing the form factor significantly compared to the previous design and making it better suited for use in smaller surgical exposures.



Imaging and Resection

Synergy Power™ System Highlights


The Synergy Power system features two handpieces: a dual-trigger rotary drill and a dedicated sagittal saw, offering surgeons precision, power, and flexibility.



Equipped with 13.2 V lithium-ion battery packs, the system ensures optimal performance and can accommodate different caseloads with both large and small sterilizable batteries. The battery chargers are designed for efficiency, charging up to four batteries simultaneously while providing clear charge level indications through simple iconography.



The Synergy Power system also includes a comprehensive selection of attachments, including drill, ream, saw, and bur attachments, all of which connect easily through an innovative and proprietary twist-collet mechanism. The dedicated sagittal saw features an open hub, ensuring easy visualization and facilitating proper cleaning. The extensive array of attachments and blades allows for seamless integration across various orthopedic procedures.



Shoulder Arthroplasty

New Eclipse™ Instruments

The Eclipse instrument system has been reimagined to:

- Streamline the workflow
- Improve ergonomics for coring and insertion of the cage screw
- Provide a calcar planer option
- Be more ASC-friendly with less instrumentation

The Eclipse system has been used for nearly two decades, with great clinical outcomes as documented in multiple studies.¹ Throughout its lifespan, there have been virtually no changes to the instrumentation and surgical technique.

The recent increase of total shoulder arthroplasty procedures in outpatient surgery centers (or ASCs) has led to a need for downsized instrument sets. This new Eclipse instrument system provides a substantial improvement in technique while reducing the overall number of devices.

A key improvement with the new set is that the trunnion sizer is used as a humeral resection protector during glenoid preparation. From a workflow perspective, this is accomplished by determining the trunnion size and attaching the sizer to an insertion handle, which is placed onto the resected humerus. The humerus is then cored through this sizer and the cage-screw length is determined with the coring instrument.

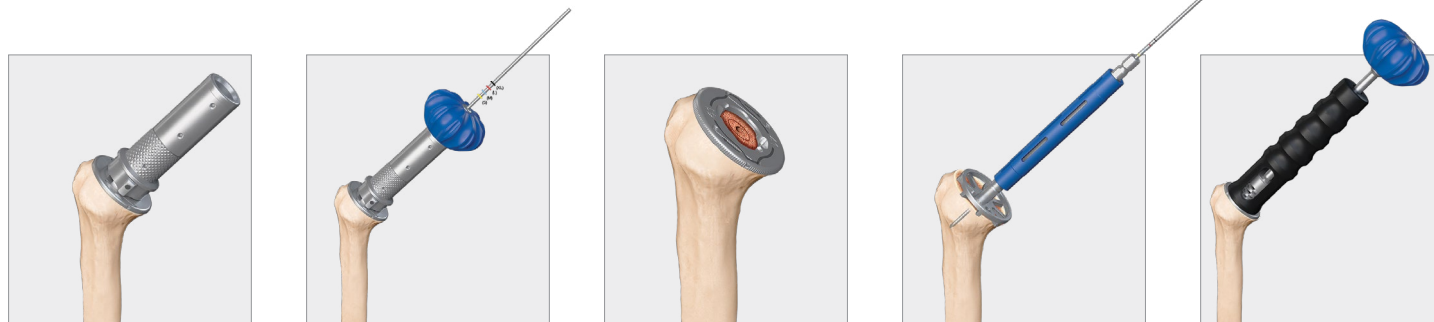
Once the glenoid has been prepared, the Eclipse trunnion and cage screw are implanted similarly to the existing technique. However, the screwdriver has been made more ergonomic with a doorknob-style handle that more readily provides the necessary torque to tighten the cage screw. This type of handle is also used for the coring step during cage-screw preparation.

While streamlining the instrumentation led to the removal of several instruments, calcar planers have been added to the system. These planers allow for smoothing out any imperfections in the humeral osteotomy.

The new Eclipse instrument system is provided in a single-level instrument tray.

Reference

1. Arthrex, Inc. Data on file (DOC1-000088-en-US). Naples, FL; 2024.



Orthobiologics

JointPreservation.Arthrex.com

JointPreservation.Arthrex.com showcases the comprehensive Arthrex cartilage repair algorithm and enhances surgeon education on the Arthrex joint preservation continuum of care.



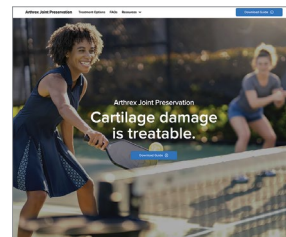
Explore curated technique pages detailing the cartilage repair algorithm, present relevant scientific literature, and reimbursement guidance. The site includes a patient outreach kit with valuable resources to help increase engagement and simplify patient education efforts.

JointPreservation.com is an interactive website designed to simplify patient education efforts and save valuable clinic time. The site's patient-friendly content explains what cartilage is, the causes of cartilage damage, and the treatment options available to help patients achieve their goals.

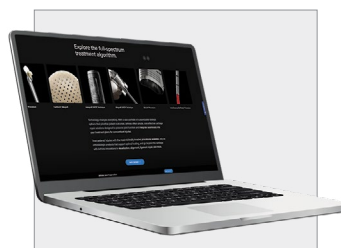
With these new joint preservation websites, Arthrex continues to showcase innovative solutions to cartilage repair and concomitant procedures.



Patient Education Brochure



Don't let the pain and limitations of cartilage damage hold you back.



Joint Preservation Surgeon Site



Joint Preservation Patient Site

Feature Article



BioACL™ Technique

Justin J. Mitchell, MD
LaCrosse, WI

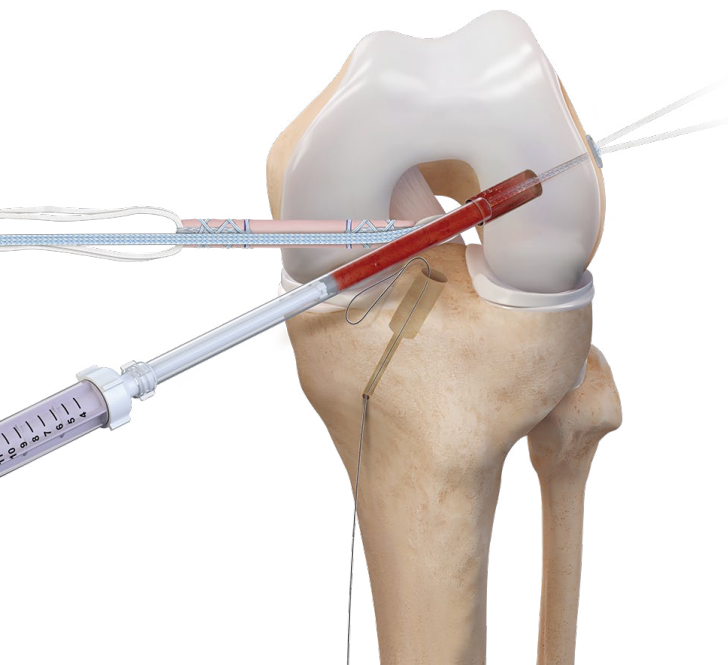
What is the difference between a standard ACL reconstruction and the BioACL technique? Why would you augment an ACL reconstruction?

While standard ACL reconstruction involves placing a graft into a reamed ACL tunnel and expecting it to incorporate into the native bone over time, the BioACL technique leverages proven orthobiologic technology to improve the graft-to-bone tunnel interface and promote more definitive bony incorporation of the graft by filling the tunnels with a composite bone graft. The BioACL technique aims to enhance bony incorporation directly and bolster graft support during the processes of remodeling and ligamentization.

How would you describe the ideal consistency of the BioACL composite graft? Any tips for achieving the right viscosity?

I usually describe the mix as having a “brownie batter” consistency, but we have affectionately coined it “BioButter.” The graft should be dense enough that it maintains form but malleable enough that it can flow smoothly through the delivery device. My typical formulation is:

- Autograft tunnel reamings
- 2.5 cc of AlloSync™ Pure demineralized bone matrix
- 3 cc of concentrated platelet-rich plasma (cPRP) from bone marrow aspirate (BMA)



How do you collect the autologous bone that is used to create the BioACL composite?

I use the GraftNet™ device to collect autograft bone. By attaching the device to the shaver handle and capturing the bone graft as it passes through the shaver, it allows for atraumatic collection of autogenous tunnel reamings without requiring additional steps during the surgery. The GraftNet device conveniently stores the autogenous bone for when we create the BioACL composite graft.

Where do you usually harvest the patient’s bone marrow from?

I have used the iliac crest, posterior superior iliac spine (PSIS), and the proximal tibia for harvesting bone marrow. After performing all three, I have found that harvesting from the proximal tibia is the most efficient, providing quality BMA at the volume I am looking for.

Who is the best candidate for the BioACL procedure?

Because of the versatility and radiographic improvements we have seen, my preference is to use the BioACL technique whenever possible for skeletally mature patients undergoing ACL reconstruction.

How has the BioACL technique helped your patients?

I have to admit, I was initially skeptical that the BioACL technique would make a significant difference for my patients. However, it quickly became clear to me that follow-up radiographs at 2 weeks, 3 months, 6 months, and 1 year demonstrated progressive bony healing and incorporation that was notably improved compared to what I typically observed with ACL reconstruction patients.


After surgery, patients love to see tangible evidence that they are healing as expected, so being able to share their x-rays clearly showing the bone tunnels progressively healing has been a true confidence builder for many of my patients.

How do you introduce the BioACL procedure to your patients?

What information do you feel is most critical to share?

Understandably, patients are concerned about short- and long-term graft failure. When we talk about the ways we can mitigate those failures, I always show my patients surgical videos of what the graft is, what the tunnels are, and how there is typically unoccupied space in those tunnels that may cause graft instability. When we discuss this, patients intuitively understand that the BioACL technique can potentially help mitigate that issue.

Feature Article



The Forgotten Fracture: Revisiting Intertrochanteric Femur Fracture Care

Alexander M. Crespo, MD
Chicago, IL

Intertrochanteric femur fractures, often termed the “forgotten fracture,” are deceptively overlooked. With a 90% success rate, treatment outcomes might appear praiseworthy—especially compared to the 70% to 80% success rates seen in surgical management of proximal humerus¹ or pilon fractures.^{2,3} Yet, the sheer volume of cases tells a different story. Annually, about 250,000 hip fractures occur in the United States, meaning a 10% failure rate yields an alarmingly high volume of revision cases.^{4,5}

This burden primarily affects one of our most vulnerable patient populations: the frail and elderly. For these patients, obtaining surgical clearance for their initial surgery is often a challenge, and the risks of postsurgical morbidity rise exponentially after revision surgeries for failed treatment. These injuries represent cases in which there is little room for error—we must get it right the first time.

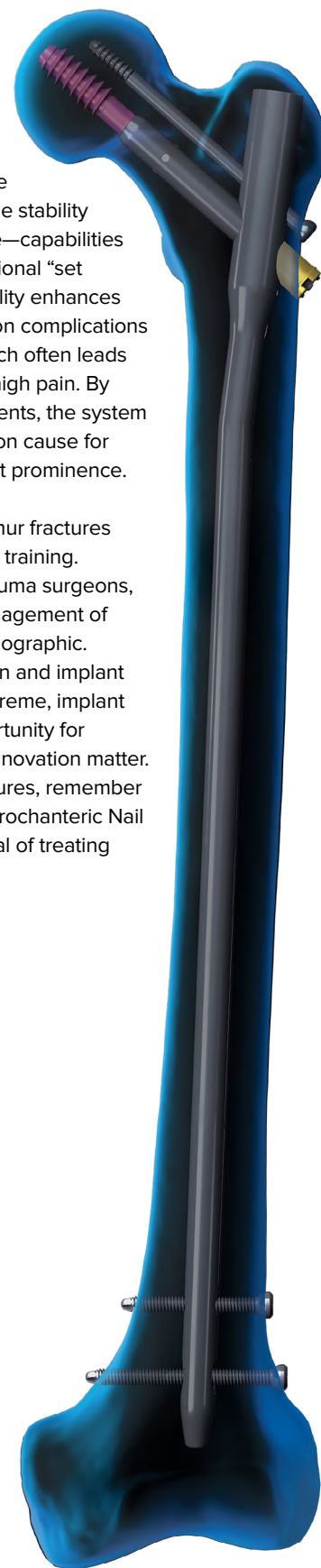
The intertrochanteric region of the femur is the most biomechanically dynamic and demanding fracture environment we treat. Unstable fracture patterns, defined as those involving significant damage to the medial femoral calcar, yield a mechanically unstable environment that requires robust fixation to allow early mobilization. Cephalomedullary nails have a decades-long history and evolution and are commonly used in the treatment of unstable intertrochanteric femur fractures. The Arthrex Trochanteric Nail System is the most modern and capable iteration in the historic family tree of cephalomedullary nailing platforms.

References

1. Kim Alrabaa RG, Ma G, Truong NM, et al. Trends in surgical treatment of proximal humeral fractures and analysis of postoperative complications over a decade in 384,158 patients. *JB JS Open Access*. 2022;7(4):e22.00008. doi:10.2106/JBJS.OA.22.00008
2. Minator Sajjadi M, Ebrahimpour A, Okhovatpour MA, Karimi A, Zandi R, Sharifzadeh A. The outcomes of pilon fracture treatment: primary open reduction and internal fixation versus two-stage approach. *Arch Bone Jt Surg*. 2018;6(5):412-419.
3. van der Vliet QMJ, Ochen Y, McTague MF, et al. Long-term outcomes after operative treatment for tibial pilon fractures. *OTA Int*. 2019;2(4):e043. doi:10.1097/O19.0000000000000043
4. Kokoroghiannis C, Aktseilis I, Deligeorgis A, Fragkomichalos E, Papadimas D, Pappadas I. Evolving concepts of stability and intramedullary fixation of intertrochanteric fractures--a review. *Injury*. 2012;43(6):686-693. doi:10.1016/j.injury.2011.05.031
5. Checketts JX, Dai Q, Zhu L, Miao Z, Shepherd S, Norris BL. Readmission rates after hip fracture: are there prefracture warning signs for patients most at risk of readmission? *J Am Acad Orthop Surg*. 2020;28(24):1017-1026. doi:10.5435/JAAOS-D-19-00751

The Arthrex Trochanteric Nail System represents cutting-edge advancement in cephalomedullary nail technology. Its telescoping cephalomedullary component, combined with locking ring and sleeve technology, delivers a unique and novel combination of fixed-angle stability and controlled fracture-site collapse—capabilities not simultaneously offered by traditional “set screw” systems. This dual functionality enhances overall stability and reduces common complications like lateral implant prominence, which often leads to trochanteric bursitis and lateral thigh pain. By minimizing lateralization of components, the system significantly lowers the most common cause for revision: symptomatic lateral implant prominence.

Caring for geriatric patients with femur fractures transcends orthopedic subspecialty training. Whether we are hand, sports, or trauma surgeons, all of us are responsible for the management of this frail and vulnerable patient demographic. While principles of fracture reduction and implant placement undoubtedly remain supreme, implant choice may also represent an opportunity for improvement: implant design and innovation matter. When treating these forgotten fractures, remember the unique features of the Arthrex Trochanteric Nail and how it may help you in your goal of treating patients better.



Feature Article



InternalBrace™ Technique for ACL Reconstruction

Patrick A. Smith, MD
Naples, FL

Dr. Smith, a pioneer in research into the InternalBrace technique for the knee, discusses his work, patient selection in study design, and evidence the technique leads to reduced ACL graft retear rates.^{1,2}

Why did you begin researching the InternalBrace technique?

Building on the initial work of *InternalBrace* augmentation procedure for Brostrom ankle stabilization, the idea was to use FiberTape® suture to protect ACL grafts during healing. Despite FiberTape suture being well established for years in rotator cuff repairs, we needed to show its use in the knee as part of the *InternalBrace* technique was safe without the joint reactions seen with earlier, problematic synthetic grafts. We started with translational canine models that showed no adverse reactions to FiberTape suture use in the joint.^{3,4}

Next, a biomechanical study showed FiberTape suture protected grafts from displacement in a time-zero model.⁵ Critically, a second biomechanical study showed that FiberTape suture is truly load sharing, not stress shielding, as the FiberTape suture was shown to experience load only at the higher loading conditions.⁶ This meant the graft would incur appropriate stress to enhance healing and remodeling at normal loads and the FiberTape suture would begin to see load only at higher load levels to limit graft elongation by increasing the overall construct stiffness, thereby serving as a “seat belt” for graft protection.⁶

How do these results translate to clinical outcomes?

In our first clinical study, we looked at 200 patients under the age of 20 who underwent ACL reconstruction with all graft types, 100 who received the *InternalBrace* technique and 100 who did not.⁷ We saw an 8% retear rate in the group without the *InternalBrace* technique but just 1% in the group with the technique.⁷ A similar 2024 study of young athletic BTB graft patients (average age = 19) showed zero retears in *InternalBrace* technique recipients versus an 8% retear rate in the control group at 5 years.² We saw similar improvement in a hamstring graft study—at 4-year follow-up, nonaugmented patients had a 24% retear rate compared to just 5.6% with the *InternalBrace* technique.⁵ Also in 2024, we published a case series on 60 of my young, cutting athlete patients (average age = 16.8 years) treated with quadriceps tendon grafts with the *InternalBrace* technique. There were zero graft retears at 3-year follow-up.⁸ It is important to note that in all of these studies, no lateral augmentation procedures were performed, just ACL reconstruction with the *InternalBrace* technique.

Why do you strictly include younger patients in your research?

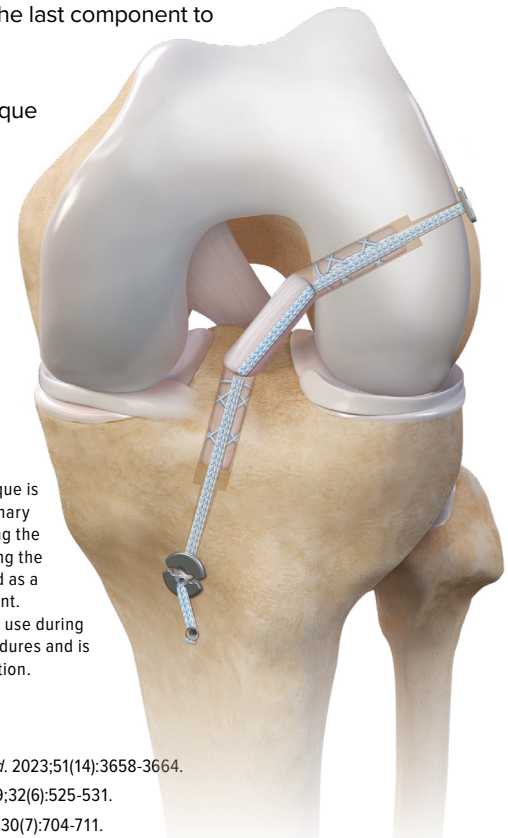
It is well documented that adult patients do not retear their grafts as much as younger people. So while I believe all ACL reconstruction patients can benefit from the *InternalBrace* technique, where the rubber meets the road is, can you take the high-risk, young, active patient group and reduce their retear rate? We’ve definitively shown the procedure works in this population and *InternalBrace* augmentation for ACL grafts reduces retears.^{1,2} This obviously is most important for patients who must undergo just one major surgery but is also beneficial to surgeons, as in my practice, I just don’t have to do challenging ACL revisions very often now.

What steps facilitate an effective InternalBrace technique?

The independent fixation technique mirrors our biomechanical results and is an essential component of the procedure’s success. In all cases, FiberTape suture is loaded through the femoral TightRope® button, which is now available with all TightRope II implants. The graft is attached to the adjustable TightRope loop. Once the graft is in place, but prior to final tensioning, I put the knee in full hyperextension and fixate the FiberTape sutures in the tibia using a SwiveLock® anchor and the Secondary Fixation Implant System. Graft fixation is then completed on the tibia, also in hyperextension, and then we cycle the knee and retension the graft, so it is always the last component to experience load.

The *InternalBrace* technique from Arthrex is the only option with preloaded implants that make it easy, reproducible, and cost effective. It is backed by a large body of peer-reviewed published literature supporting its use.

The *InternalBrace* surgical technique is intended only to augment the primary repair/reconstruction by expanding the area of tissue approximation during the healing period and is not intended as a replacement for the native ligament. The *InternalBrace* technique is for use during soft tissue-to-bone fixation procedures and is not cleared for bone-to-bone fixation.



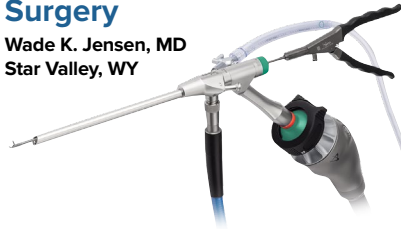References

1. Wilson WT, et al. *Am J Sports Med.* 2023;51(14):3658-3664.
2. Smith PA, et al. *J Knee Surg.* 2019;32(6):525-531.
3. Cook JL, et al. *J Knee Surg.* 2017;30(7):704-711.
4. Smith PA, et al. *J Knee Surg.* 2020;33(10):1047-1054.
5. Bachmaier S, et al. *Arthroscopy.* 2018;34(2):490-499.
6. Daniel AV, et al. *Arthroscopy.* Published online March 20, 2024.
7. Daniel AV, et al. *Orthop J Sports Med.* 2023;11(7):23259671231178026.
8. Daniel AV, et al. *Arthroscopy.* 2024;40(9):2455-2464.



Why I Pursued Endoscopic Spine Surgery

Wade K. Jensen, MD
Star Valley, WY



My journey to endoscopic spine surgery wasn't an obvious one. I trained in complex spinal deformities and revisions and specialized in osteotomies to correct sagittal imbalances. My practice was maximally invasive, not minimally invasive. A pivotal moment at the 2017 North American Spine Society (NASS) Annual Meeting, where I observed a minimally invasive endoscopic thoracic discectomy, sparked a shift in my thinking. The elegance and precision of the endoscopic approach, along with its potential benefits for patients, intrigued me. I began to question if there was a less invasive, equally effective way to address spinal pathologies.

Driven by curiosity and a desire to improve patient care, I immersed myself in endoscopic training, attending courses, visiting experienced surgeons, and practicing on cadavers. Though the learning curve was slow, the rewards were undeniable. Endoscopic spine surgery unlocked new possibilities, allowing me to offer patients less invasive options with faster recovery times,¹ fewer postoperative complications,²⁻⁴ and minimal scarring. It also enabled me to treat conditions like facet-mediated low-back pain. The endoscope has become a powerful tool, allowing me to visualize and access spinal structures with unprecedented clarity.

As my endoscopic practice grew, I witnessed firsthand the positive impact on my patients' lives. They returned to activities sooner, with less pain and fewer complications. It has become routine for all my cases each week to be endoscopic.

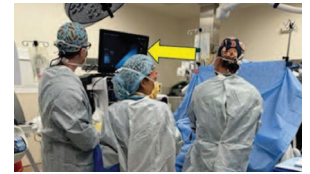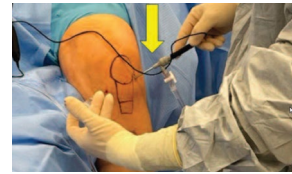
To fellow spine surgeons who have yet to embrace endoscopy, I encourage you to explore its potential. The learning curve may seem daunting, but training options have markedly improved, and the benefits for both patients and surgeons are undeniable. Step outside your comfort zone and discover the transformative power of endoscopic spine surgery, where the focus is not just on advanced technology but also on a philosophy of care that prioritizes minimally invasive techniques and patient well-being.

Review the [Endoscopic Spine Learning Curve](#).

References

1. Gadjradj PS, Broulikova HM, van Dongen JM, et al. *Br J Sports Med*. Published online February 20, 2022. doi:10.1136/bjsports-2021-104808
2. Ruetten S, Komp M, Merk H, Godolias G. *J Neurosurg Spine*. 2007;6(6):521-530.
3. Polikandriotis JA, Hudak EM, Perry MW. *J Orthop*. 2013;10(1):13-16.
4. Page PS, Ammanuel SG, Josiah DT. *Cureus*. 2022;14(5):e25202.

The Nano Difference: Comparing Nano Arthroscopy to Traditional Arthroscopy



Arthrex spoke with Sean McMillan, DO (Burlington, NJ), to discuss a newly published study¹ by his team comparing a needle arthroscope to a traditional arthroscope for visualization during a partial meniscectomy. The study focused on the postoperative outcomes of the 68 participants, highlighting differences in muscle strength in the quadriceps. One of the most common orthopedic procedures in the United States, a meniscectomy often has a lengthy recovery period. Dr. McMillan emphasized how using local anesthesia and needle scopes allows patients to walk out the door and return to work on the same day, a similar experience to going to the dentist. After working with high-level athletes trying to quickly return to sport post procedure, Dr. McMillan elected to do an independent, physician-driven study evaluating the NanoNeedle Scope system compared to traditional arthroscopy for everyday patients.

In addition to being a less invasive procedure, Dr. McMillan said the NanoNeedle Scope helps him combat operative challenges during the ongoing fluid shortage. Using the NanoNeedle Scope in routine knee arthroscopies, Dr. McMillan can perform procedures using less than 500 cc of fluid, whereas up to 3000 cc of fluid can be required during a traditional meniscectomy. With this significant conservation, he is consistently able to hang smaller bags of fluid and perform cases in a timely manner.

The results of the study underscore Nano arthroscopy as a viable alternative to traditional arthroscopy for a partial meniscectomy. While providing better postoperative muscle strength retention, Nano arthroscopy results in less pain, less reliance on opioids, and less surgical fluid requirements.¹ Because many residents whom Dr. McMillan trains are comfortable using needle scopes compared to traditional arthroscopes, he believes that the results of the study will help surgeons shift the standard of care to Nano arthroscopy for this and other common procedures. Dr. McMillan noted he's lucky to be a part of such a progressive health system and believes that continual research on Nano arthroscopy will lead to better outcomes going forward.

Reference

1. Ford E, Pontes M, Chayes D, McMillan S. Arthroscopic partial meniscectomy using a needle arthroscope for visualization resulted in greater retention of postoperative quadriceps muscle strength compared to traditional arthroscope. *Surg Technol Int*. Published online November 18, 2024.

Pointers and Pearls



The Newest Virtual Implant Positioning™ (VIP™) Feature: Metal Segmentation and Revision Planning

Brian C. Werner, MD
Charlottesville, VA

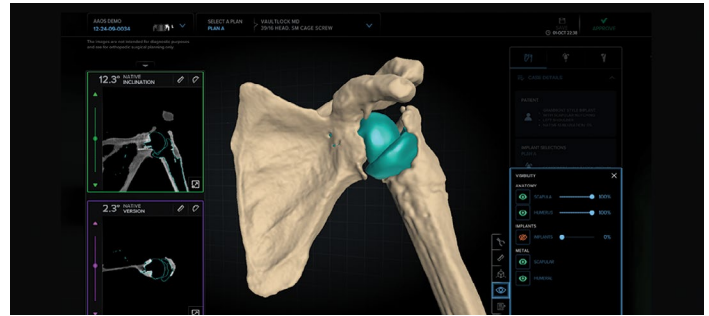
The VIP system has recently added the capability to segment metal from CT scans. This feature allows for planning and receiving transfer instrumentation for revision cases. What value does this new offering provide to your practice?

Most surgeons agree that CT-based preoperative planning with software like the VIP system is ideal for shoulder arthroplasty. However, many preoperative planning software systems do not allow planning of these more challenging revision arthroplasty cases due to the presence of metal scatter in the CT scan. Before the introduction of this new planning capability, I would embark on my most challenging cases with a one-stage revision and no thorough preoperative plan.

The new VIP metal segmentation feature is an exciting advancement, enabling surgeons to preoperatively plan cases with preexisting metallic implants. VIP planners can now separate the preexisting metal implants from the osseous structures on both the glenoid and the humerus. When the plan is delivered to the surgeon, they can visualize the existing metal implants and plan new implants as we typically do in the VIP software.

The addition of metal segmentation allows surgeons to use VIP preoperative planning for their most challenging cases and still use the same transfer technology they trust.

The value this adds to the VIP system—for both surgeons and patients—is significant. First, we will likely execute our revision cases with more accuracy. Second, it will inevitably reduce the number of staged revisions; I can confidently approach a revision case without the need to stage now that I can plan with metal segmentation. Third, even in the nonrevision arthroplasty scenario, such as in patients with metal glenoid anchors or other implants like screws or staples from prior instability surgeries, a plan can now be executed with a transfer guide, enhancing the surgeon's ability to correct deformities and achieve secure fixation.



Are there specific anatomies or revision scenarios where VIP metal segmentation provides the most value?

This addition provides immense value for any case that would have been rejected due to metal in the scan, including patients with antibiotic spacers, metal glenoid anchors, screws or staples, and prior arthroplasty components. In addition to providing the ability to plan the revision implants and obtain a targeter, this technology allows me to isolate and examine the previously implanted components in three dimensions. I have had several cases where I was able to identify broken screws on baseplates that require specific extraction devices that I would have otherwise missed on 2-dimensional imaging.

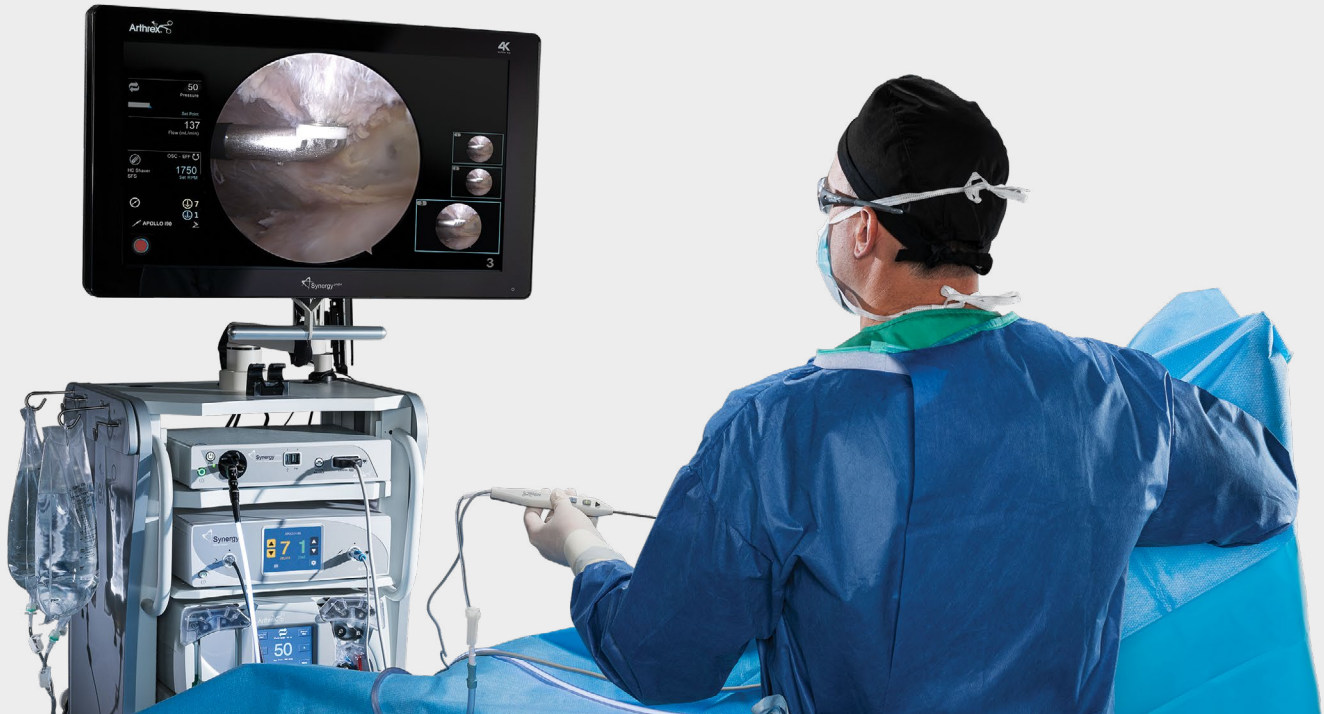VIP metal segmentation provides a lot of value in challenging B2 glenoid anatomies that have metal scatter present due to prior instability surgery. These are typically younger male patients, and I like augmented Modular Glenoid System (MGS) baseplates to correct the glenoid deformity. Before the release of this new capability, I really wanted to optimize component positioning but was unable to plan or generate targeter settings. This is a complex scenario that is now easy to plan in the VIP system and much easier to execute clinically.

Do you have any best practices or pearls you can share after having used this technology?

Prior research has demonstrated the benefit of transfer technology for glenoid pin and implant placement. A challenge for surgeons such as myself who perform a significant number of revisions and challenging primary arthroplasty cases, however, was the rejection of a CT scan for the presence of metal, leaving us without these tools for our hardest cases. This problem is completely solved with the new metal segmentation capability in the VIP system.

I encourage surgeons to upload all of their cases with metal to the VIP system, to understand how significant of an improvement this is. When you receive your plan from the VIP team, be sure to use the visibility settings to show and hide the metal components to visualize the remaining bone when you are finalizing the implant positioning. If you are like me and would lean toward a two-stage revision when you were unable to confidently place revision implants, you will find quite frequently that a single-stage procedure is sufficient once you have the confidence of a VIP plan and targeter for your revision.

What's in My Bag?



Apollo^{RF}® Rotator Cuff Repair

Asheesh Bedi, MD
Chicago, IL

Can you discuss your experience using the Apollo^{RF} i90 probe?

The RF probe is a staple of most arthroscopic procedures, and that's certainly true for shoulder surgeries. Having a reliable RF ablation probe is crucial for rotator cuff repairs. It plays a vital role in performing a comprehensive and efficient bursectomy, providing you with a "room with a view" to effectively visualize the tear pattern. The Apollo^{RF} i90 probe's electrode head design is optimized for easy entry into the joint and to navigate and work around confined anatomy. Its controlled ablation allows for precise dissection in delicate areas, such as, around blood vessels or the coracoacromial ligament. Its reliability and controlled ablation zone enhance surgical precision and efficiency for implant placement. I also like to use the Apollo^{RF} i90 probe as a marking tool, allowing me to reliably mark implant placement with minimal ablation, which enhances my comfort during the process to know I'm protecting adjacent tissue.

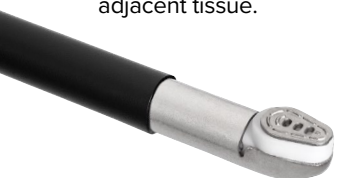What piqued your interest in using the Apollo^{RF} i90 probe in the CuffMend procedure?

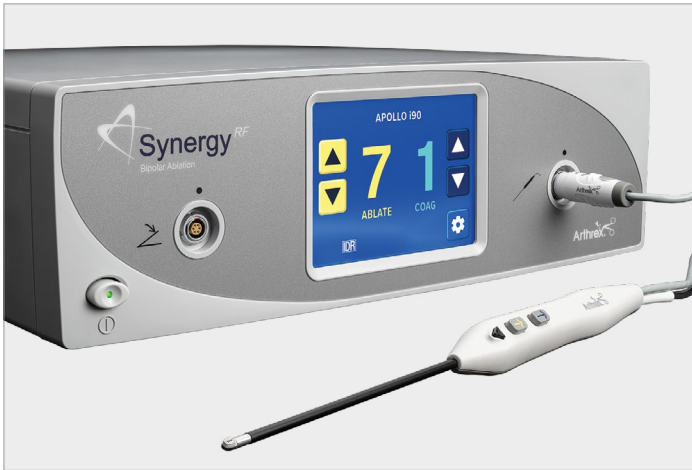Surgeons are evolving their techniques beyond simply repairing the rotator cuff, focusing on optimal anchor spacing and positioning to ensure effective draping over the greater tuberosity footprint. Properly placed anchors optimize constructs, like SpeedBridge™ repairs or a more complex extended SpeedBridge repair.

The new Apollo^{RF} i90 marking method simplifies this by allowing precise anchor positioning without extensive dissection. Additionally, when augmenting the rotator cuff with the CuffMend procedure, placing extra fixation around lateral anchors becomes crucial, emphasizing the importance of careful spacing.

What attributes of the Apollo^{RF} i90 probe are you particularly drawn to?

Many surgeons have shared common expectations of RF devices in the operating room: They want the device to efficiently ablate tissue and be easily introduced into and out of the joint without causing trauma. The Apollo^{RF} i90 probe excels in these areas. A key factor for RF is the ability to address clogging and maintain suction.¹ In the subacromial space, thickened acromial bursa often requires frequent clearing when using probes, which can be frustrating. However, with the Apollo^{RF} i90 probe, I have not encountered this issue, making it highly valuable.





In what other procedures is the Apollo^{RF} i90 probe beneficial?

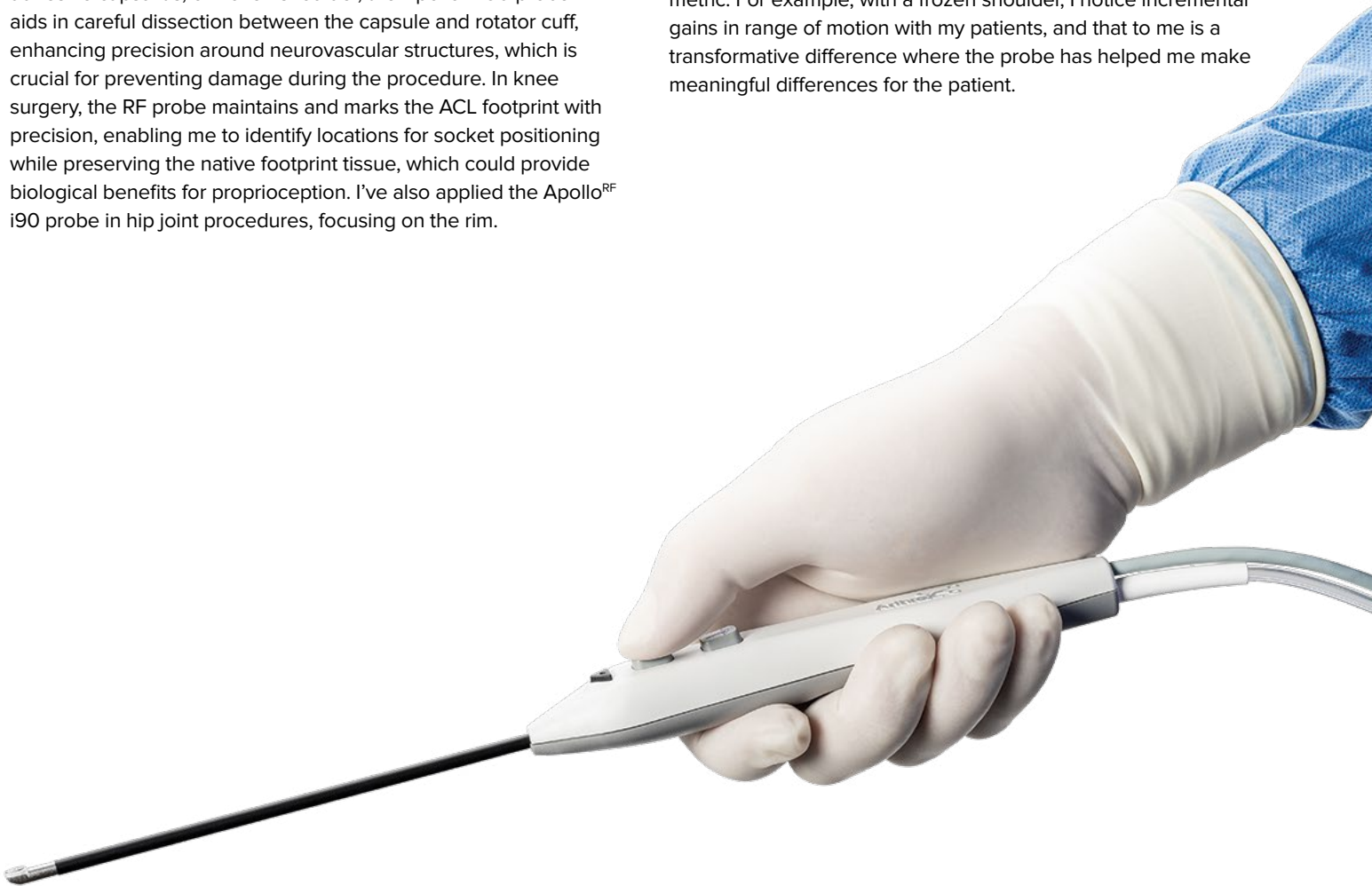The Apollo i90 probe's torpedo-shaped electrode paired with its controlled ablation allows for precise dissection during surgeries, particularly when mobilizing the capsular labrum. Additionally, for adhesive capsulitis, or frozen shoulder, the Apollo^{RF} i90 probe aids in careful dissection between the capsule and rotator cuff, enhancing precision around neurovascular structures, which is crucial for preventing damage during the procedure. In knee surgery, the RF probe maintains and marks the ACL footprint with precision, enabling me to identify locations for socket positioning while preserving the native footprint tissue, which could provide biological benefits for proprioception. I've also applied the Apollo^{RF} i90 probe in hip joint procedures, focusing on the rim.

What would you tell a surgeon who is considering adopting the Apollo^{RF} i90 probe?

I would encourage peers to trial the device specifically and consider where in their surgical practice they could find some opportunity for improvement. As I looked critically at my own practice, I found the Apollo^{RF} i90 probe enhances reliability and efficiency, addressing past challenges. I would encourage other surgeons to do the same exploration. At this point, the Apollo^{RF} i90 probe is the default RF probe for all my surgical procedures.

Is there anything else you would like to share?

A lot of credit to Arthrex for continued innovation that is always focused on helping surgeons like me treat our patients better. The Apollo^{RF} i90 probe is one such example where RF technology is not something new in and of itself, and yet there are ways to improve on existing technology to make us that much better at surgery. Some of these incremental differences, whether it's precise ablation around the deltoid and soft tissue, precise dissection, or an ability to execute a more thorough procedure, do make meaningful differences for our patients, and that's always my metric. For example, with a frozen shoulder, I notice incremental gains in range of motion with my patients, and that to me is a transformative difference where the probe has helped me make meaningful differences for the patient.



Reference

1. Arthrex, Inc. Data on file (AR-9831 clog performance design verification). Naples, FL; 2021.

What's in My Bag?



PARS Achilles Midsubstance SpeedBridge™ Repair

Andrew R. Hsu, MD
Irvine, CA

When did you first gain experience with minimally invasive Achilles tendon repairs?

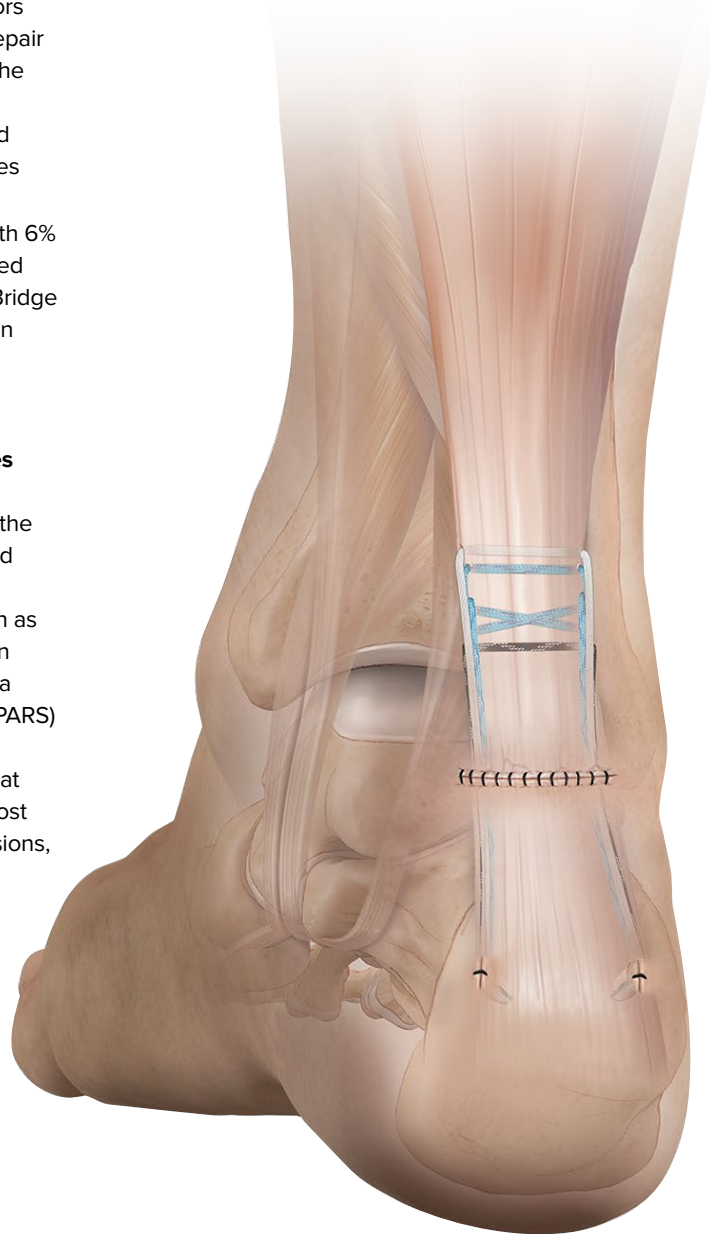
I was fortunate to do my foot and ankle fellowship at the OrthoCarolina Foot & Ankle Institute in 2014, where my mentors taught me the original Arthrex PARS (percutaneous Achilles repair system) technique early on. I was immediately impressed by the procedure and its outcomes, and it became a primary clinical and research interest of mine. During fellowship, we published one of the largest single-center series of PARS vs open Achilles repairs¹ showing that the number of patients who returned to baseline activities by 5 months was higher following PARS, with 6% fewer total complications compared to open repair. As I finished fellowship in 2015, the Arthrex Achilles Midsubstance SpeedBridge (AMSS) technique was coming out. It became the next iteration of minimally invasive Achilles repair, which I adopted early on and explored.²

What are the main advantages of minimally invasive Achilles tendon repairs compared to traditional open repair?

Minimal dissection with maximal fixation. A primary benefit of the PARS and AMSS techniques is that the tendon can be repaired with minimal soft-tissue dissection, thus better preserving the integrity of the native tissues and reducing complications such as wound dehiscence, superficial and deep infection, and tendon scarring. Another benefit is the ability to repair the Achilles in a robust fashion with either SutureTape-to-SutureTape fixation (PARS) or SutureTape-to-SwiveLock® anchor fixation in bone (AMSS). Both PARS and AMSS reduce dissection and foreign material at the site of the rupture where tissue quality is the worst and most susceptible to suture pullout. The combination of smaller incisions, decreased dissection, and strong fixation ultimately allows surgeons to be able to rehab patients faster in terms of motion and weight-bearing.

What were the early differences in patient outcomes you experienced with the PARS system compared to open repair?

Decreased wound complications was the first and most significant difference with the PARS system compared to open repair. Not having to worry about delayed wound healing and wound infections was a significant improvement in my practice that allowed me to focus more on rehab and progress with Achilles patients. Since we did not have to wait as long for wounds to heal, we were able to get PARS patients working on motion and weight-bearing weeks faster than open-repair patients. This led to patients treated with PARS being able to return to regular activities and athletics significantly faster than patients treated with open repair.



You transitioned your practice from the PARS technique to the Achilles Midsubstance SpeedBridge™ procedure; what were the main reasons for this?

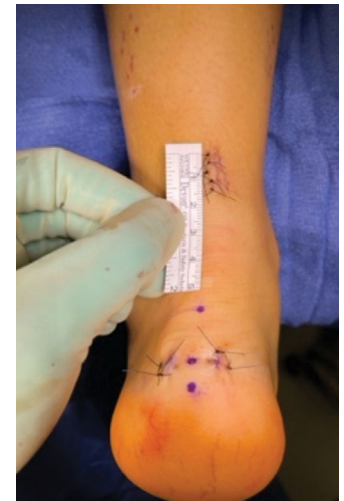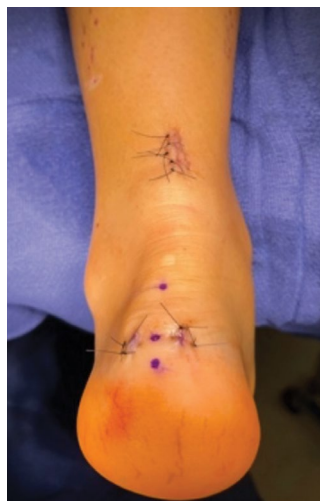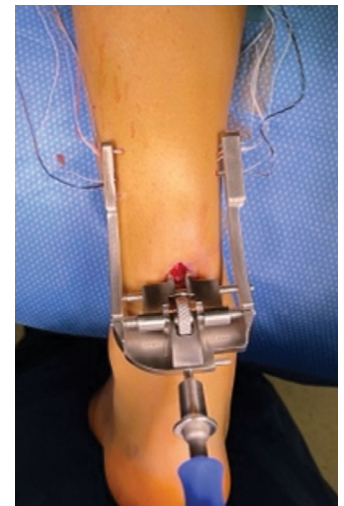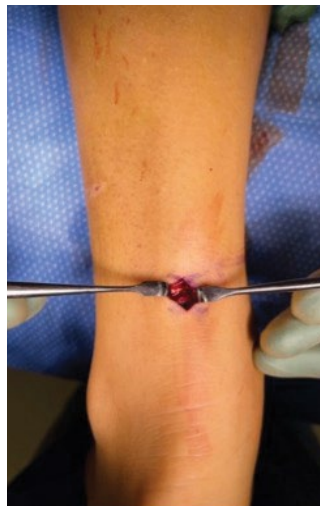While the PARS technique works for the majority of Achilles midsubstance ruptures, there are patients who have poor tendon quality, more distal ruptures, or delayed presentation where I think AMSS is more advantageous given its ability to directly repair proximal tendon to bone. AMSS allows the surgeon to bypass the areas of poor tendon quality and set the resting tension of the Achilles directly into bone with 3.9 mm SwiveLock® anchors. The direct tendon-to-bone repair allows immediate plantar flexion range of motion exercises and early weight-bearing with decreased concern for sutures pulling through tendon.

Working at an academic medical center where I teach residents of various backgrounds and training levels, I appreciated that the AMSS technique can be easily taught and reproduced since there is less reliance on end-to-end repair and subjective knot tying at the rupture site. AMSS connects healthy Achilles tendon proximal to the rupture site directly to healthy bone along the insertion of the Achilles tendon, creating a “bridge-plate fixation” strategy for tendon repair.

What is your typical patient recovery time from Achilles Midsubstance SpeedBridge surgery?

After surgery, patients are typically non-weight-bearing for the first 2 weeks with early plantar flexion range-of-motion exercises in a tall CAM boot with two heel lifts. Sutures are removed at 2 weeks and patients are weight-bearing as tolerated in a tall CAM boot from weeks 2-5, removing a heel lift every 3 to 4 days. Patients are transitioned out the CAM boot into a regular shoe with physical therapy at week 5 with a rehab focus on high repetitions of controlled double- and single-limb heel raises. Regular activities are resumed by 8 to 10 weeks.

High-impact activities such as running and jumping and dorsiflexion past neutral are permitted at week 12 to prevent tendon elongation during the initial healing process. Depending on individual patient demographics, some individuals can begin immediate weight-bearing after surgery with a more aggressive rehab program.³



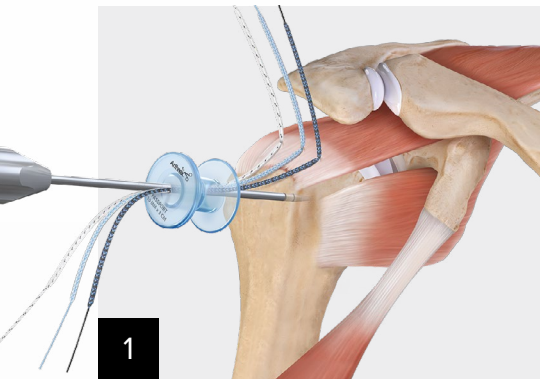
References

1. Hsu AR, Jones CP, Cohen BE, Davis WH, Ellington JK, Anderson RB. Clinical outcomes and complications of percutaneous Achilles repair system versus open technique for acute Achilles tendon ruptures. *Foot Ankle Int.* 2015;36(11):1279-1286. doi:10.1177/1071100715589632
2. Hsu AR. Limited-incision knotless Achilles tendon repair. *Am J Orthop* (Belle Mead NJ). 2016;45(7):E487-E492.
3. McWilliam JR, Mackay G. The Internal Brace for midsubstance Achilles ruptures. *Foot Ankle Int.* 2016;37(7):794-800. doi:10.1177/1071100716653373

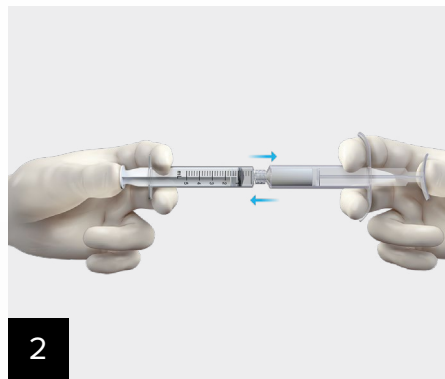IN THE Loop

BoneSync™ Bone Void Filler for Augmentation of Poor-Quality Bone in the Lateral Row

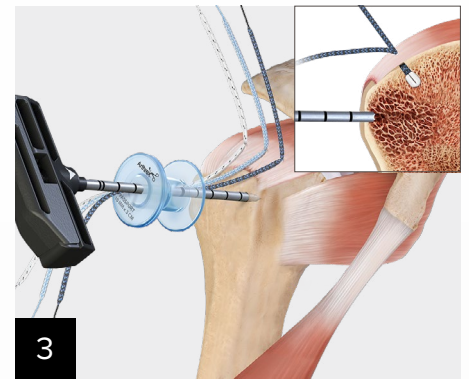
BoneSync calcium phosphate cement is a fast-setting, collagen-infused, and provisional hardware-compatible synthetic bone void filler. The 1 cc size BoneSync calcium phosphate cement is optimal for augmenting lateral-row anchors during rotator cuff repairs where poor bone quality is present.



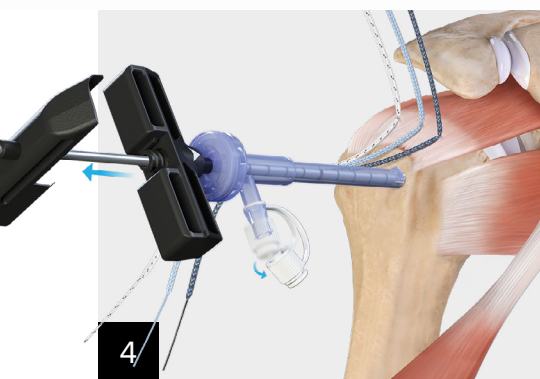
1
After implanting the medial anchors, an anchor punch can be used to assess bone quality in the lateral-row anchor site. If augmentation is needed, BoneSync cement can be used to supplement poor-quality bone.



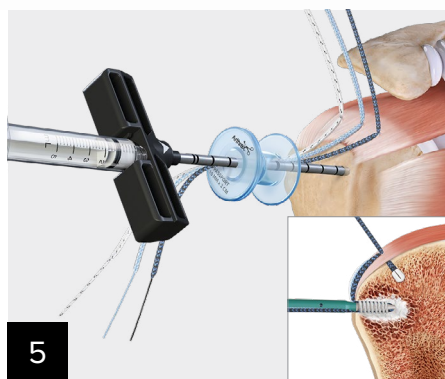
2
Begin the mixing process by drawing 0.8 cc of saline into a syringe, which is attached to the BoneSync syringe. Mix back and forth for 60 seconds.



3
Insert the delivery cannula 2-3 mm into the pilot hole created by the anchor punch.

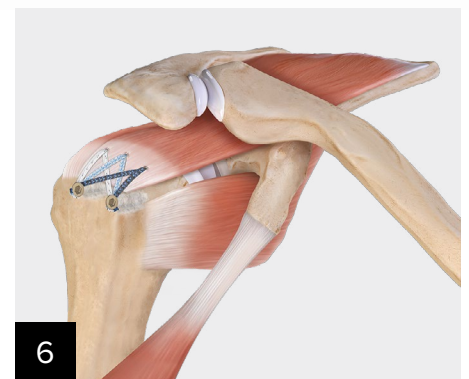

4
Pearl: A 5.5 mm cannula can be used to improve depth control of the cannula and the Luer cap can be removed to evacuate any excess cement.



5
Remove the inner trocar from the cannula, attach the BoneSync syringe, and inject the cement into the cannula.

Insert the inner trocar into the cannula to deliver the remaining cement to the intended site. Insert the SwiveLock® anchor within 2 minutes of cement implantation.



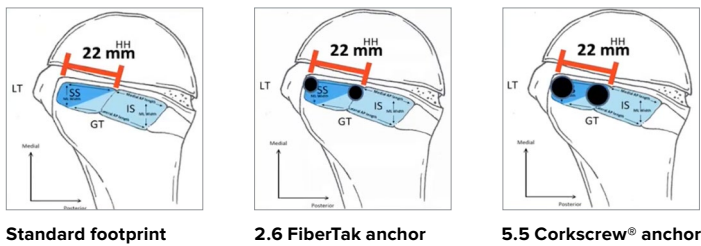
6
Repeat steps for the second lateral-row anchor and complete the remaining steps for the rotator cuff repair technique.

FiberTak® SpeedBridge™ Repair: An Anatomy-Preserving Approach to Rotator Cuff Repair

The FiberTak SpeedBridge procedure builds on the principles of the SpeedBridge repair with features that better preserve the anatomic footprint of the rotator cuff.

Footprint Preservation

With a smaller anchor size, the FiberTak SpeedBridge construct maximizes the amount of bone being compressed to the footprint. For example, the average footprint size of the supraspinatus is 22 mm. Using two 5.5 mm anchors violates nearly 50% of the footprint, reducing the amount of tendon touching bone, whereas using 2.6 FiberTak RC anchors violates only 24% of the footprint.¹ Additionally, these smaller anchors sit beneath the cortex, thereby maximizing the tendon-to-footprint interface.



Strength Comparison

A study by Patrick J. Denard and Joseph D. Lamplot compared the strength and compression of a standard 4-anchor repair against the FiberTak SpeedBridge construct.¹ Three all-suture anchors were compared to 2 hard-bodied anchors on the medial row. The results showed no significant differences in cyclic displacement or cyclic stiffness. There was also no significant difference in load to failure between the constructs, with lateral anchor pullout being the most common mode of failure in both groups. This indicates that the FiberTak SpeedBridge construct provides fixation strength comparable to trusted SpeedBridge constructs (Table 1).

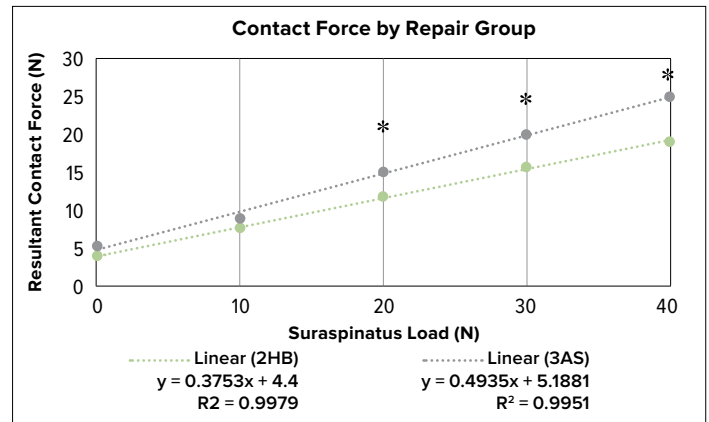
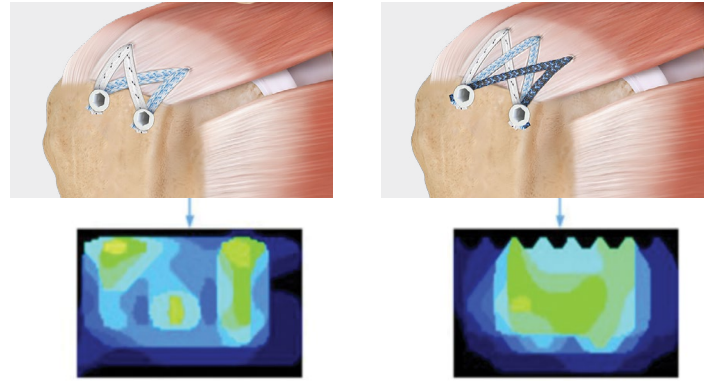
Table 1. Biomechanical Comparison of the 3AS and 2HB Constructs

Outcome Data	3AS*	2HB*	P Value
Creep, mm	0.35 ± 0.2	0.21 ± 0.1	.275
Cyclic displacement, mm			
1 cycle	1.41 ± 1.0	1.57 ± 1.0	.616
30 cycles	1.95 ± 0.8	1.73 ± 0.6	.497
100 cycles	3.64 ± 2.5	2.78 ± 1.5	.190
Cyclic stiffness, N/mm			
Cycle 1	58.4 ± 46.4	56.1 ± 36.0	.928
Cycle 30	78.4 ± 30.1	74.8 ± 23.6	.822
Cycle 100	80.9 ± 30.9	77.0 ± 23.1	.810
Postcyclic stiffness, N/mm	76.8 ± 13.2	81.53 ± 23.7	.649
Displacement at 200 N, mm	7.62 ± 2.3	8.10 ± 3.9	.749
Load to failure, N	718.2 ± 344.0	608.7 ± 134.5	.445

*2HB, two hard-body anchors; 3AS, 3 medial all-suture anchors

Footprint Compression

The primary goal of rotator cuff repair is to maximize the compression of the tendon against the bone. The FiberTak SpeedBridge construct achieves this goal, with 30% more compression compared to traditional techniques and more consistent compression across the footprint.¹



Clinical Relevance

All-suture anchors are smaller than hard-body anchors. The smaller anchors allow for placement of an additional all-suture medial anchor to improve contact force and potentially improve rotator cuff healing when compared to hard-body anchors.¹

With more than 15 years of clinical success with the SpeedBridge construct, the FiberTak SpeedBridge repair innovates upon a trusted foundation and provides additional advantages to help surgeons treat their patients better.



Reference

- Hoffman TR, Lamplot JD, McClish SJ, Payne C, Denard PJ. Three medial all suture anchors improves contact force compared to two hard body anchors in a biomechanical two-tendon rotator cuff tear model. *Arthrosc Sports Med Rehabil.* 2022;4(5):e1601-e1607. doi:10.1016/j.asmr.2022.05.012

Research Corner

Histological Analysis of Compressed Biceps Autograft for Augmentation of Arthroscopic Rotator Cuff Repair

Rotator cuff healing after repair remains a challenge. Biologic augmentation of rotator cuff repair in patients at risk for retear has therefore gained popularity. Recently, use of an autograft biceps from the normally discarded portion after biceps tenodesis has been described as a potential augmentation patch for rotator cuff repair.¹ While earlier preparation systems have been shown to compromise tenocyte viability, the Autograft Tissue Compression System (ATCS) was recently reported as a point-of-care processor for adapting the long head of the biceps after tenodesis.²

After performing a biceps tenodesis, the normally discarded biceps can be saved and repurposed as an augmentation graft. The ATCS system uses a press with compression plates to compress a graft into the desired shape and thickness. By placing the segment of biceps into the compression plates (Figure A) and applying pressure with the press for approximately 4 minutes (Figure B), a graft for augmentation can be created (Figure C).

To evaluate the viability of tenocytes in the biceps tendon after compression with the ATCS, a section of normally discarded biceps was split longitudinally in 55 patients.² One half was left intact, and the other half was prepared using the ATCS system. More than 90% of specimens retained complete viability and there was no difference between compressed and noncompressed specimens.

Overall, autograft biceps compression preserves tenocyte viability at time of insertion for augmentation of rotator cuff pathology and is a promising option for biologic augmentation.

References

1. Colbath G, Murray A, Siatkowski S, et al. Autograft long head biceps tendon can be used as a scaffold for biologically augmenting rotator cuff repairs. *Arthroscopy*. 2022;38(1):38-48. doi:10.1016/j.arthro.2021.05.064
2. Brinkman JC, Makovicka JL, Denard PJ, et al. Compression of an autograft biceps into an augmentation patch does not cause mechanical damage to the tenocyte. *Arthroscopy*. Published online September 26, 2024. doi:10.1016/j.arthro.2024.09.029



The views expressed in this newsletter reflect the experience and opinions of the presenting surgeons and do not necessarily reflect those of Arthrex, Inc.

Any description of technique is provided as an educational tool and clinical aid to assist properly licensed medical professionals in the usage of specific Arthrex products. As part of this professional usage, the medical professional must use their professional judgment in making any final determinations in product usage and technique. In doing so, the medical professional should rely on their own training and experience and should conduct a thorough review of pertinent medical literature and the product's directions for use. Postoperative management is patient-specific and dependent on the treating professional's assessment. Individual results will vary and not all patients will experience the same postoperative activity level or outcomes.

Products may not be available in all markets because product availability is subject to the regulatory or medical practices in individual markets. Please contact your Arthrex representative if you have questions about availability of products in your area.

arthrex.com

© 2025-02 Arthrex, Inc. All rights reserved. LN1-000623-en-US_A

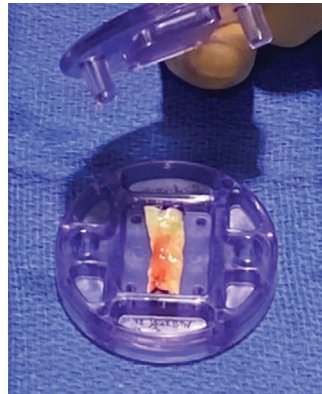


Figure A

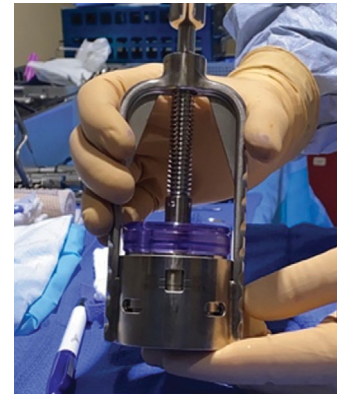

Figure B

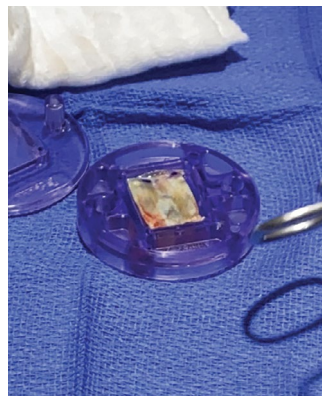
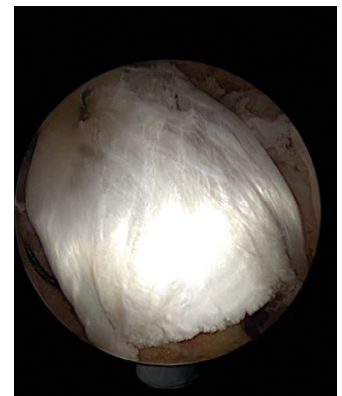

Figure C



Implanted Compressed Biceps Patch



Scope This Out is an informational newsletter designed to educate orthopedic surgeons on new products, state-of-the-art surgical procedures, and “pearls” to assist in improving surgical skills.

Arthrex's Corporate Headquarters is located in Naples, Florida. Additional locations include a global division in Munich, Germany, as well as several subsidiaries and distribution centers throughout the world.