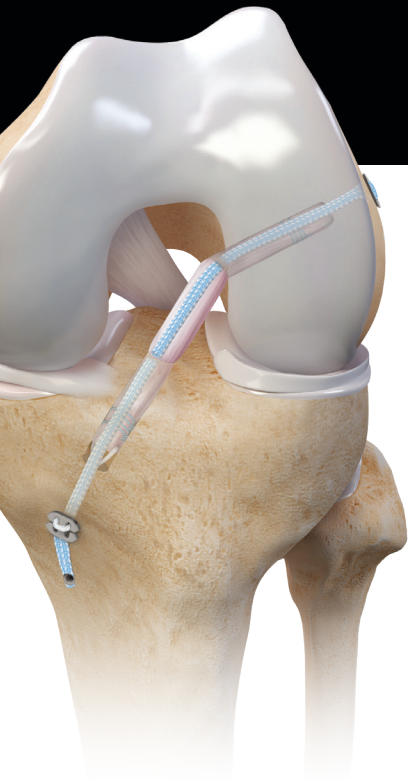


InternalBrace™ Technique: Knee Applications



The *InternalBrace* procedure, which has been proven to be efficacious,¹ can be applied in various ways throughout the knee. This augmentation helps prevent excess range of motion during the healing phase and may reduce the chances of secondary injury.^{2,3}

In the setting of ACL reconstruction, the *InternalBrace* procedure helps protect against various modes of failure including creep and irreversible stretch, traumatic tearing, and slippage of the tendon-bone interface.^{4,5} The *InternalBrace* technique may also help protect small and vulnerable hamstring ACL reconstruction grafts from these modes of failure.^{4,5}

Use the *InternalBrace* procedure to augment collateral ligament repairs and reconstructions and provide improved biomechanics, including greater stiffness and maximum load.⁶ Anatomic repair with augmentation may allow for early treatment using native tissues, while still providing a biomechanical environment conducive to early rehabilitation and motion.² Compared to reconstruction techniques, there are several additional benefits of augmenting collateral ligament repairs including smaller drill holes and implants, no harvest-site morbidity with allograft, and no risk of tunnel convergence in multiligament procedures.

In Vivo Citations: Clinical Outcomes

Burton DA,
Schaefer EJ,
Shu HT,
Bodendorfer BM,
Argintar EH

[Primary anterior cruciate ligament repair using suture tape augmentation: a case series of 29 patients with minimum 2-year follow-up.](#) *Arthroscopy.* 2021;37(4):1235-1241. doi:10.1016/j.arthro.2020.11.034

- The purpose of this study is to evaluate clinical outcomes and patient-reported outcomes of patients who underwent primary ACL repair using suture tape augmentation.
- In this Level IV prospective case series, patients with an average age of 32.2 ± 7.2 years and a proximal tear of the ACL who underwent primary ACL repair with a minimum 2-year follow-up were included.
- Primary surgical repair of proximal ACL tears using suture tape augmentation results in a low rate of revision surgery, which 2 of 29 (6.9%) patients required.

Connolly PT,
Zittel KW,
Panish BJ,
Rigor PD,
Argintar EH

[A comparison of postoperative pain between anterior cruciate ligament reconstruction and repair.](#) *Eur J Orthop Surg Traumatol.* 2021;10.1007/s00590-020-02859-0. doi:10.1007/s00590-020-02859-0

- This comparison included 36 ACL repair patients and 71 ACL reconstruction patients.
- Patients who underwent ACL repair experienced less short-term postoperative pain and were prescribed fewer narcotics compared to patients who underwent ACL reconstruction.
- The mean visual pain score was significantly lower for ACL repair patients compared to ACL reconstruction patients.

The *InternalBrace* surgical technique is intended only to augment the primary repair/reconstruction by expanding the area of tissue approximation during the healing period and is not intended as a replacement for the native ligament. The *InternalBrace* technique is for use during soft tissue-to-bone fixation procedures and is not cleared for bone-to-bone fixation.



Noonan BC,
Bachmaier S,
Wijdicks CA,
Bedi A

[Independent suture tape reinforcement of tripled smaller-diameter and quadrupled grafts for anterior cruciate ligament reconstruction with tibial screw fixation: a biomechanical full construct model.](#) *Arthroscopy*. 2020;36(2):481-489. doi:10.1016/j.arthro.2019.06.036

- This study compared the effect of high-strength suture tape reinforcement (using the *InternalBrace*™ procedure) on dynamic elongation, stiffness behavior, and ultimate failure load in comparison to standard ACL reconstruction with small-diameter soft-tissue grafts.
- Tripled small-diameter and standard quadrupled tendon grafts were tested with and without suture tape reinforcement using an adjustable-loop device (ALD) for femoral fixation and an interference screw for tibial fixation.
- Tripled constructs showed a significantly worse performance than quadrupled constructs at higher loads. Reinforcement with suture tape significantly reduced total elongation in both the tripled and quadrupled groups. Failure loads were also significantly improved in the suture-augmented groups.
- The authors concluded that suture tape reinforcement for ACL reconstruction may provide an option for protecting autografts and allografts against irreversible lengthening during the maturation and remodeling phases of healing.

Bodendorfer BM,
Michaelson EM,
Shu HT,
et al

[Suture augmented versus standard anterior cruciate ligament reconstruction: a matched comparative analysis.](#) *Arthroscopy*. 2019;35(7):2114-2122. doi:10.1016/j.arthro.2019.01.054

- Authors compared outcomes between anterior cruciate ligament reconstruction (ACLR) using hamstring grafts with and without suture augmentation (SA).
- “Patients who underwent ACLR with hamstring autografts or allografts with a minimum 2-year follow-up were reviewed.”
- “Postoperative average daily (0.60 ± 1.25 vs 1.66 ± 1.90) and maximum daily pain (1.57 ± 1.83 vs 3.35 ± 2.28) were significantly lower for the SA group ($P < .014$). SA was significantly correlated with improved time to return to preinjury activity level (9.17 ± 2.06 vs 12.88 ± 3.94 months; $P = .002$) and percentage of preinjury activity level ($93.33\% \pm 13.22\%$ vs $83.17\% \pm 17.69\%$; $P = .010$). There was a trend toward improved rate of return to preinjury activity level for SA.”
- Compared to standard hamstring ACLRs, the authors found suture-augmented hamstring ACLRs to be associated with improved PROMs, less pain, and a higher percentage of and earlier return to preinjury activity level without evidence of overconstraint.

Heusdens CHW,
Hopper GP,
Dossche L,
Roelant E,
Mackay GM

[Anterior cruciate ligament repair with independent suture tape reinforcement: a case series with 2-year follow-up.](#) *Knee Surg Sports Traumatol Arthrosc*. 2019;27(1):60-67. doi:10.1007/s00167-018-5239-1

- Forty-two patients with an acute ACL rupture and subsequent repair with independent suture tape reinforcement were followed for a minimum 2-year period.
- Patients with midsubstance, distal ruptures, poor tissue quality, retracted remnants, or multiligament injuries were excluded.
- Significant improvements in KOOS, VAS-pain, and VR-12 physical scores and a significant decrease of the Marx activity scale in comparison to pre-op scores were demonstrated. Two of the 42 patients (4.8%) reported a rerupture.
- This study confirms that ACL repair with this technique is a viable treatment option for patients with acute, nonretracted proximal ACL ruptures of good tissue quality.



Smith PA,
Bradley JP,
Konicek J,
Bley JA,
Wijdicks CA

[Independent suture tape internal brace reinforcement of bone–patellar tendon–bone allografts: biomechanical assessment in a full-ACL reconstruction laboratory model.](#) *J Knee Surg.* 2020;33(10):1047-1054. doi:10.1055/s-0039-1692649

- This study evaluated the effects of an internal brace on the biomechanical properties of ACL reconstruction in a full-construct experimental model.
- “Three groups (n=10 each) were tested in a full-construct porcine-bone model with human bone-patellar tendon-bone allografts using different reconstruction techniques: interference screw fixation on femur and tibia (S-S group), adjustable-loop device (ALD) fixation on the femur with tibial interference screw without suture tape (ALD-S group), and with internal brace (ALD-S-IB group).”
- “The ALD-S-IB group (2.9 ± 0.8 mm) displaced significantly less than the ALD-S (4.2 ± 0.9 mm; $p=0.015$) and S-S group (4.3 ± 1.1 mm; $p=0.017$). No significant difference was found between the ALD-S and the S-S group. Construct stiffness was significantly higher for the ALD-S-IB group (156 ± 23 N/mm) and the ALD-S group (122 ± 28 N/mm) than for the S-S group (104 ± 40 N/mm; $p=0.003$ and $p=0.0042$), but there was no significant difference between both ALD groups.”
- The authors concluded that these results indicate that internal bracing used with BTB grafts in ACL reconstruction improve construct biomechanics, which has clinical implications regarding initial construct stability.

Mackay G,
Anthony IC,
Jenkins PJ,
Blyth M

[Anterior cruciate ligament repair revisited. Preliminary results of primary repair with internal brace ligament augmentation: a case series.](#) *Orthop Muscul Syst.* 2015;4(2):1000188. doi:10.4172/2161-0533.1000188

- Authors aimed to assess outcomes and complications of ACL repair using the *InternalBrace*™ procedure at a minimum follow-up of 1 year.
- Sixty-eight consecutive patients who underwent ACL repair using the *InternalBrace* procedure were followed for a minimum 1-year follow-up. KOOS and WOMAC scores were collected at set time points using an online outcomes system.
- Improvement was observed in all KOOS and WOMAC domains, with the greatest improvement occurring in the first 3 months.
- This study demonstrates that the ACL repair using the *InternalBrace* procedure is comparable with early ACL reconstruction results. There were 4 reinterventions, including one for rerupture.



Matava MJ,
Koscso J,
Melara L,
Bogunovic L

In Vitro Citations: Biomechanical Validation

Suture tape augmentation improves the biomechanical performance of bone-patellar tendon-bone grafts used for anterior cruciate ligament reconstruction. *Arthroscopy*. 2021;37(11):3335-3343. doi:10.1016/j.arthro.2021.04.053

- In this study, the authors used human BPTB grafts (10 mm × 20 mm bone plugs on both sides) to reconstruct the ACL in juvenile porcine knees. Both groups used 8 mm-diameter biocomposite interference screws for fixation in the femur and tibia.
- The augmentation group differed from the control in that a FiberTape® suture for the *InternalBrace*™ technique was fixed independent of the graft using a TightRope® button on the femur and a SwiveLock® anchor on the tibia prior to fixation of the graft.
- Suture tape augmentation resulted in statistically significant improvements of time-zero biomechanical properties in terms of increased stiffness (104% increase) and ultimate failure load (57% increase) while not negatively affecting cyclic elongation, which may reduce the graft failure rate in a clinical setting.

van Eck CF,
Nakamura T,
Price T,
Linde M,
Smolinski P

Suture tape augmentation improves laxity of MCL repair in the ACL reconstructed knee. *Knee Surg Sports Traumatol Arthrosc*. 2021;29(8):2545-2552. doi:10.1007/s00167-020-06386-7

- This study compared the biomechanical effects of MCL repair with suture tape using the *InternalBrace* procedure to standalone MCL suture repair in the setting of a concomitant ACL reconstruction using a six-degrees-of-freedom robotic system.
- The authors found that MCL repair with suture tape augmentation improved valgus and external rotation laxity when compared to standalone MCL repair.
- The suture tape augmentation construct did not lead to overconstraint of the joint.
- The authors note that these findings suggest that including MCL repair with suture tape augmentation in a combined ACL-reconstruction-MCL-repair procedure may result in lower failure rates and less residual laxity, shorter immobilization times, and faster return to play.

Bachmaier S,
Smith PA,
Bley J,
Wijdicks CA

Independent suture tape reinforcement of small and standard diameter grafts for anterior cruciate ligament reconstruction: a biomechanical full construct model. *Arthroscopy*. 2018;34(2):490-499. doi:10.1016/j.arthro.2017.10.037

- This study compared dynamic elongation, stiffness, and ultimate load of standard and small grafts with and without suture tape reinforcement (using the *InternalBrace* procedure).
- Suture reinforcement of a small-diameter graft significantly reduced dynamic elongation (38%). A 15% decrease in dynamic elongation was also observed in a standard-diameter graft. The ultimate load of the small and standard grafts improved by 64% and 40% when compared to their respective controls.
- The authors concluded that independent suture tape reinforcement (using the *InternalBrace* procedure) of soft-tissue grafts for ACLR leads to significantly reduced elongation and higher ultimate load. The suture tape reinforcement technique may decrease the risk of graft tears, particularly when a small graft is used.



Gilmer BB,
Crall T,
DeLong J,
Kubo T,
Mackay G,
Jani SS

[Biomechanical analysis of internal bracing for treatment of medial knee injuries.](#) *Orthopedics*. 2016;39(3):e532-e537. doi:10.3928/01477447-20160427-13

- The authors evaluated posteromedial anatomic repair with internal bracing and compared it with the intact state, repair alone, and allograft reconstruction.
- Three groups of 9 cadaveric, fresh-frozen matched pairs (54 knees) were tested to failure at 30° under valgus load in a biomechanical testing apparatus.
- The authors concluded that posteromedial knee repair with internal bracing is superior to repair alone and similar to allograft reconstruction for all parameters measured. They also eliminated the concern of overconstraint of the medial knee in the internal brace group.

In Vivo Citations: Translational Research

Soreide E,
Denbeigh JM,
Lewallen EA,
et al

[In vivo assessment of high-molecular-weight polyethylene core suture tape for intra-articular ligament reconstruction.](#) *Bone Joint J*. 2019;101-B(10):1238-1247. doi:10.1302/0301-620X.101B10.BJJ-2018-1282.R2

- Eighteen rabbits underwent bilateral ACL reconstruction with autograft, FiberTape® suture, or FiberTape suture-augmented autograft.
- At eight weeks, both FiberTape suture alone and FiberTape suture-augmented autograft demonstrated improved ultimate load to failure, elongation, and energy absorption when compared with autograft. FiberTape suture samples also demonstrated increased bone mineral density in the bone tunnel.
- The authors concluded that FiberTape suture increases the biomechanical performance of intra-articular ligament reconstructions in a verified rabbit model at eight weeks. Additionally, FiberTape suture did not demonstrate any deleterious effects, such as adversely affecting bone tunnel healing or invoking a prolonged elevation in inflammation.

Smith PA,
Bozynski CC,
Kuroki K,
Henrich SM,
Wijdicks CA,
Cook JL

[Intra-articular biocompatibility of multistranded, long-chain polyethylene suture tape in a canine ACL model.](#) *J Knee Surg*. 2019;32(06):525-531. doi:10.1055/s-0038-1655765

- The authors sought to assess the intra-articular use of a nonabsorbable braided suture tape for its biocompatibility when implanted next to the native ACL in a canine model.
- No severe inflammatory or immune responses, bony erosions, or premature OA development were noted during the 6-month study period, even in a “worst-case” scenario model.
- Results of this study support the biocompatibility and safety of intra-articular suture tape for augmentation of ACLR or repairs.
- “The hypothesis was accepted as study results support the biocompatibility of suture tape in the canine knee.”



Cook JL,
Smith P,
Stannard JP,
et al

[A canine arthroscopic anterior cruciate ligament reconstruction model for study of synthetic augmentation of tendon allografts.](#) *J Knee Surg.* 2017;30(7):704-711. doi:10.1055/s-0036-1597618

- The study objective was to describe and validate a translational canine model for all-inside ACL reconstruction (ACLR) using a quadriceps tendon allograft with internal brace (QTIB).
- Results suggest that a QTIB construct used in ACLR can provide sustained knee stability and function without the development of premature OA in a valid preclinical model.
- The authors concluded that the configuration of the QTIB prevented early failure, allowed for direct, four-zone graft-to-bone healing, and functional graft remodeling while avoiding problems noted with use of all-synthetic grafts.

Systematic Review/Meta-Analysis

Wilson WT,
Hopper GP,
Banger MS,
Blyth MJG,
Riches PE,
MacKay GM

[Anterior cruciate ligament repair with internal brace augmentation: a systematic review.](#) *Knee.* 2022;35:192-200. doi:10.1016/j.knee.2022.03.009

- This systematic review and meta-analysis was the first to examine ACL primary repair using the *InternalBrace*™ technique exclusive of other techniques and included 9 studies consisting of 346 patients with a mean age of 32.5 years and a mean minimum 2-year follow-up.
- The authors concluded that ACL repair using the *InternalBrace* technique is a safe technique for treatment of proximal ruptures, which have the most potential for healing, with a failure rate of 10.4% at a mean follow-up of 2.7 years.
- Meta-analysis of PROMs—including KOOS, Lysholm, and IKDC—revealed mean scores greater than 87% of max for all and mean side-to-side difference in AP laxity of 1.2 mm.

E A Mackenzie C,
Huntington LS,
Tulloch S

[Suture tape augmentation of anterior cruciate ligament reconstruction increases biomechanical stability: a systematic review of biomechanical, animal, and clinical studies.](#) *Arthroscopy.* 2022;S0749-8063(21)01127-0. doi:10.1016/j.arthro.2021.12.036

- This systematic review summarized 22 technical, animal, biomechanical, and clinical studies focused on ACRs augmented with suture tape to assess the pertinent literature currently available and “determine what evidence exists to support and oppose the technique in clinical practice.”
- Cited advantages of suture-tape-augmented grafts include evidence of gradually increasing load-sharing characteristics, 12.2% to 73.0% greater load to failure, and 17.0% to 60.2% reduced elongation.
- No significant difference in complications, rates of ligamentization, histological findings, or evidence of stress shielding was found.
- PROMS in clinical studies include improved or equivalent outcomes in IKDC scores and return to sport.

van Eck CF,
Limpisvasti O,
ElAttrache NS

[Is there a role for internal bracing and repair of the anterior cruciate ligament? A systematic literature review.](#) *Am J Sports Med.* 2018;46(9):2291-2298. doi:10.1177/0363546517717956

- An electronic database search was conducted, identifying 89 publications describing preclinical and clinical studies on outcomes of ACL repair.
- Proximal ACL tears demonstrated better healing potential than distal or mid-substance tears in the setting of primary repair. Internal bracing increased the success rate of ACL repair.
- “ACL repair may be a viable option in young patients with acute, proximal tears. The use of internal bracing, biological augmentation, and scaffold tissue may increase the success rate of repair.”



Internal/Brace™ Ligament Augmentation Technique Citations

Lavender C,
Johnson B,
Singh V,
Dennis E,
Torres L

The Lavender fertilized anterior cruciate ligament reconstruction: a quadriceps tendon all-inside reconstruction fertilized with bone marrow concentrate, demineralized bone matrix, and autograft bone. *Arthrosc Tech.* 2019;8(9):e1019-e1023. doi:10.1016/j.eats.2019.05.013

Golden T,
Friedman AMB,
Jazayeri R,
Sanderson B,
Levy E

Primary repair of the medial collateral ligament with a double row suture technique and suture tape augmentation for acute tibial-sided injuries. *Arthrosc Tech.* 2019;8(4):e395-e398. doi:10.1016/j.eats.2018.11.018

Sherman B,
Vardiabasis N,
Schlechter JA

Suture tape augmentation repair of the medial patellofemoral ligament. *Arthrosc Tech.* 2019;8(10):e1159-e1162. doi:10.1016/j.eats.2019.06.003

McGee R,
Daggett M,
Jacks A,
Hoang V,
Theobald HA

Patellar tendon graft anterior cruciate ligament reconstruction technique with suture tape augmentation. *Arthrosc Tech.* 2019;8(4):e355-e361. doi:10.1016/j.eats.2018.11.003

Monaco E,
Mazza D,
Redler A,
Drogo P,
Wolf MR,
Ferretti A

Anterolateral ligament repair augmented with suture tape in acute anterior cruciate ligament reconstruction. *Arthrosc Tech.* 2109;8(4):e369-e373. doi:10.1016/j.eats.2018.11.014

Dabis J,
Wilson A

Repair and augmentation with internal brace in the multiligament injured knee. *Clin Sports Med.* 2019;38(2):275-283. doi:10.1016/j.csm.2018.11.008

Hopper GP,
Heusdens CHW,
Dossche L,
Mackay GM

Posterior cruciate ligament repair with suture tape augmentation. *Arthrosc Tech.* 2019;8(1):e7-e10. doi:10.1016/j.eats.2018.08.022

Hopper GP,
Heusdens CHW,
Dossche L,
Mackay GM

Medial patellofemoral ligament repair with suture tape augmentation. *Arthrosc Tech.* 2019;8(1):e1-e5. doi:10.1016/j.eats.2018.08.021

Hopper GP,
Heusdens CHW,
Dossche L,
Mackay GM

Posterolateral corner repair with suture tape augmentation. *Arthrosc Tech.* 2018;7(12):e1299-e1303. doi:10.1016/j.eats.2018.08.018

Saper MG

Quadriceps tendon autograft anterior cruciate ligament reconstruction with independent suture tape reinforcement. *Arthrosc Tech.* 2018;7(11):e1221-e1229. doi:10.1016/j.eats.2018.08.007

Heusdens CHW,
Hopper GP,
Dossche L,
Mackay GM

Anterior cruciate ligament repair using independent suture tape reinforcement. *Arthrosc Tech.* 2018;7(7):e747-e753. doi:10.1016/j.eats.2018.03.007

Trasolini NA,
Hatch GFR

Suture augmentation: an alternative to reconstruction for incomplete posterior cruciate ligament injuries in the multiple ligament-injured knee. *Arthrosc Tech.* 2018;7(3):e239-e243. doi:10.1016/j.eats.2017.08.074



Daggett M,
Redler A,
Witte K

[Anterior cruciate ligament reconstruction with suture tape augmentation.](#) *Arthrosc Tech.* 2018;7(4):e385-e389. doi:10.1016/j.eats.2017.10.010

Trofa DP,
Sonnenfeld JJ,
Song DJ,
Lynch TS

[Distal knee medial collateral ligament repair with suture augmentation.](#) *Arthrosc Tech.* 2018;7(9):e921-e926. doi:10.1016/j.eats.2018.05.001

Jonkergouw A,
Van der List JP,
DiFelice GS

[Multiligament repair with suture augmentation in a knee dislocation with medial-sided injury.](#) *Arthrosc Tech.* 2018;7(8):e839-e843. doi:10.1016/j.eats.2018.04.006

Aboalata M,
Elazab A,
Halawa A,
Imhoff AB,
Bassiouny Y

[Internal suture augmentation technique to protect the anterior cruciate ligament reconstruction graft.](#) *Arthrosc Tech.* 2017;6(5):e1633-e1638. doi:10.1016/j.eats.2017.06.020

van der List JP,
DiFelice GS

[Primary repair of the medial collateral ligament with internal bracing.](#) *Arthrosc Tech.* 2017;6(4):e933-e937. doi:10.1016/j.eats.2017.03.003

Smith PA,
Bley JA

[Allograft anterior cruciate ligament reconstruction utilizing internal brace augmentation.](#) *Arthrosc Tech.* 2016;5(5):e1143-e1147. doi:10.1016/j.eats.2016.06.007

Lubowitz JH,
MacKay G,
Gilmer B

[Knee medial collateral ligament and posteromedial corner anatomic repair with internal bracing.](#) *Arthrosc Tech.* 2014;3(4):e505-e508. doi:10.1016/j.eats.2014.05.008

References

1. Bodendorfer BM, Michaelson EM, Shu HT, et al. Suture augmented versus standard anterior cruciate ligament reconstruction: a matched comparative analysis. *Arthroscopy.* 2019;35(7):2114-2122. doi:10.1016/j.arthro.2019.01.054
2. Mackay GM, Blyth MJ, Anthony I, Hopper GP, Ribbans WJ. A review of ligament augmentation with the *InternalBrace*[™]: the surgical principle is described for the lateral ankle ligament and ACL repair in particular, and a comprehensive review of other surgical applications and techniques is presented. *Surg Technol Int.* 2015;26:239-255.
3. Smith PA, Bley JA. Allograft anterior cruciate ligament reconstruction utilizing internal brace augmentation. *Arthrosc Tech.* 2016;5(5):e1143-e1147. doi:10.1016/j.eats.2016.06.007
4. Bachmaier S, Smith PA, Bley J, Wijdicks CA. Independent suture tape reinforcement of small and standard diameter grafts for anterior cruciate ligament reconstruction: A biomechanical full construct model. *Arthroscopy.* 2018;34(2):490-499. doi:10.1016/j.arthro.2017.10.037
5. Bedi A. Editorial commentary: buckle up surgeons: "safety belt" reinforcement of knee anterior cruciate ligament reconstruction grafts. *Arthroscopy.* 2018;34(2):500-501. doi:10.1016/j.arthro.2017.12.009
6. Arthrex, Inc. LA1-00086-EN_B. Naples, FL; 2018.