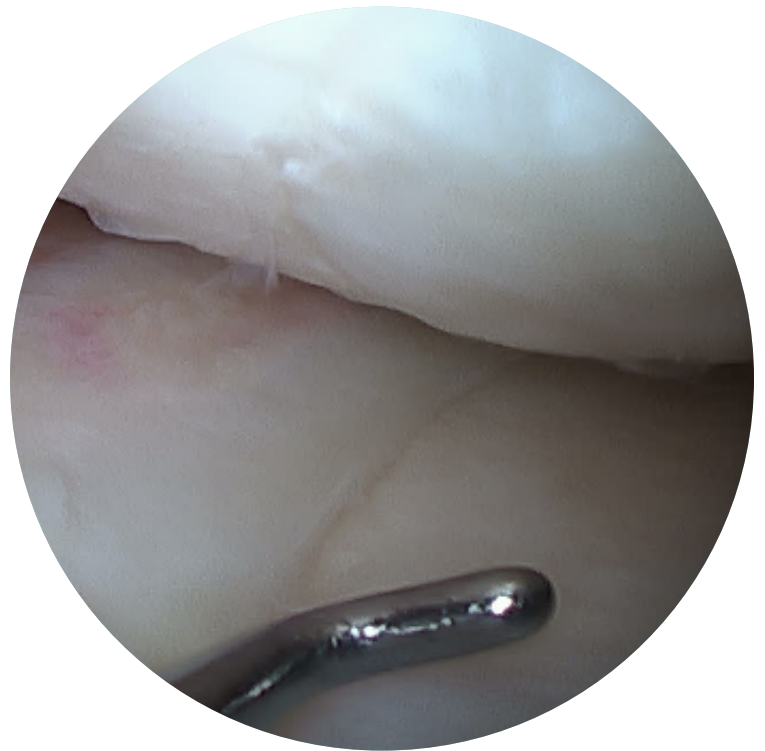


# Technique Guide for **Meniscus Allograft Transplantation**

By: James L. Carey, M.D., M.P.H.



# INTRODUCTION

Different techniques of meniscus allograft transplantation with bone blocks or a bone bridge have been described and detailed. However, there have been very few descriptions of surgical techniques of meniscus allograft transplantation using only soft tissue. The soft tissue procedure has been performed at several high-volume centers, and its acceptance has been increasing, in general.

## ADVANTAGES

---

- » Technique familiarity
- » Inclusive of skills used in soft-tissue repair of the shoulder and meniscal root repair
- » Uses common instruments in Sports Medicine
- » Less chance for neurovascular disruption
- » Less post-operative pain, which minimizes rehabilitation issues
- » More flexibility for anatomic graft placement in recipient knee
- » Most consistent with transplant principles of “replacing like with like” while minimizing involvement of other structures

## DISADVANTAGES

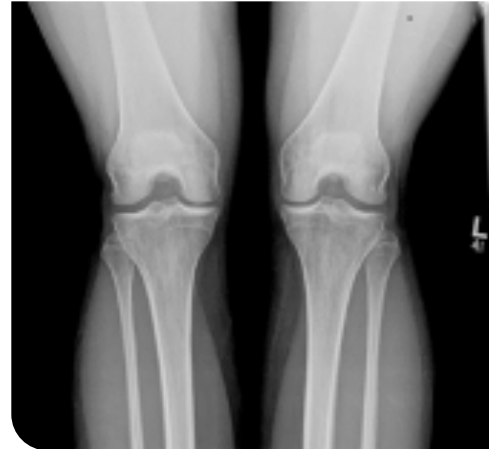---

- » Suture management more challenging
- » Weaker initial fixation about roots
- » Possible suboptimal hoop stress distribution compared to anatomically placed meniscus allograft with bone

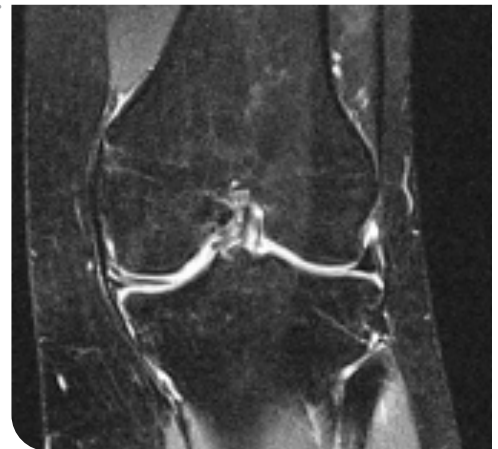
# EVALUATE PATIENT AND INDIVIDUALIZE CARE

- A. **Review the patient demographics**, which ideally describe an active person between the ages of 15 to 50.
- B. **Listen to the patient history**, including prior partial meniscectomy. Is there persistent pain, especially with impact?
- C. **Perform a physical examination**, with attention to tenderness about the joint line and a possible effusion. *Assess the ligaments, especially the rotational stability provided by ACL grafts!*

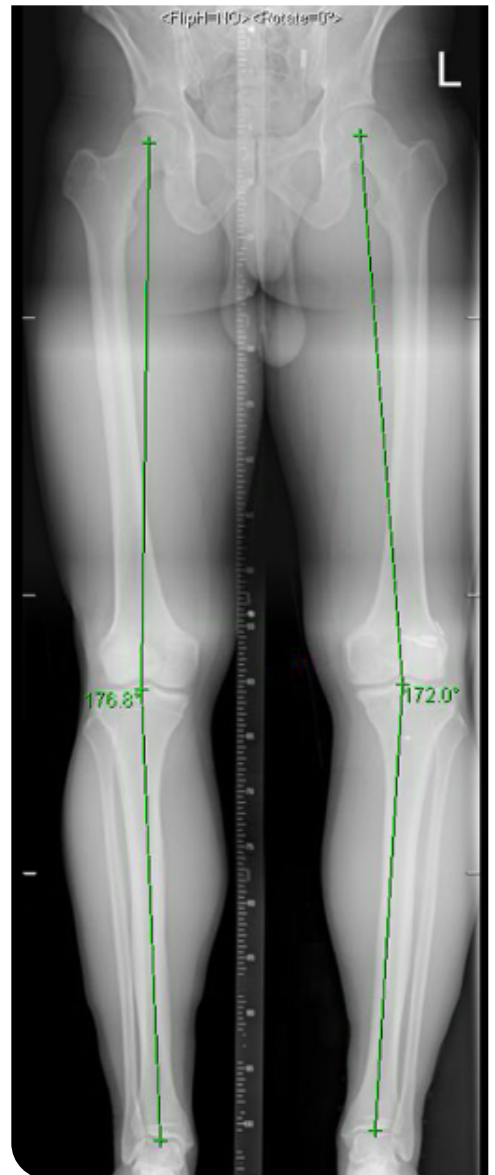
- 
- D. **View weight-bearing X-rays**, which need to demonstrate preservation of joint space.



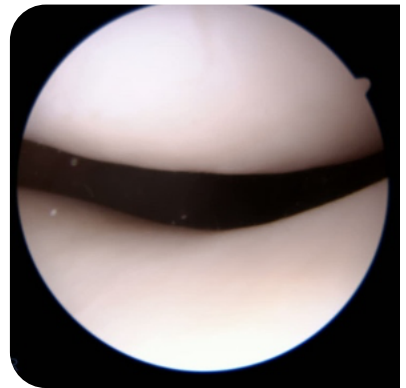
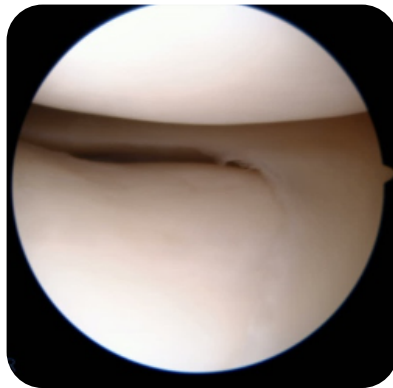
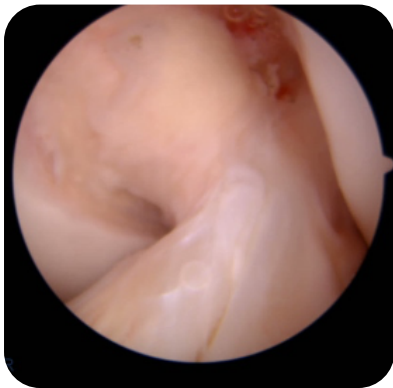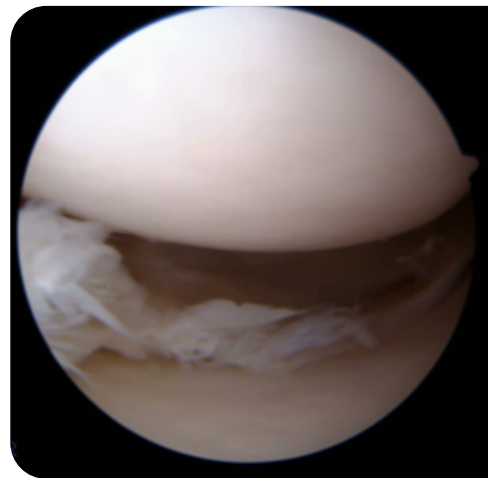
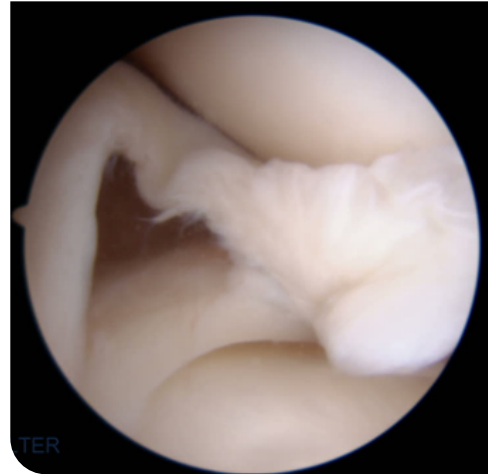
- 
- E. **Examine the MRI**, noting a diminutive meniscus, possible increased signal in the adjacent subchondral bone. *Assess the integrity of the articular cartilage!*



F. Acquire full-length alignment imaging, visualizing from the hip to the ankle. Assess the mechanical axis!



G. **Optionally perform arthroscopy**, confirming meniscal deficiency, assessing articular cartilage, and assessing ligament function during exam under anesthesia. This may also provide some symptomatic relief, especially in the setting of flipped bucket handle fragments and delaminating cartilage.



## CONCOMITANT PROCEDURE PLANNING

A few essential things to consider in order to improve success rate follow:

- A. ACL deficiency requires ACL reconstruction;
- B. Focal articular cartilage defect requires cartilage repair; and
- C. Malalignment requires osteotomy.

## CONTRA-INDICATIONS

First, meniscus transplantation is contra-indicated when the compartment receiving the meniscus has arthritis -- that is, the regional loss of articular cartilage. Second, meniscus transplantation is contra-indicated when the patient is unable to comply with post-operative rehabilitation.

## REVIEW EXPECTATIONS WITH PATIENT DURING SHARED DECISION-MAKING PROCESS

Immediate post-operative period typically includes six (6) weeks of crutches, motion limits, weight bearing precautions, and a brace. Physical therapy and rehabilitation last 12 to 18 weeks. Note: The healing rate and long-term survivorship are not greater than 85%. Finally, address the disease transmission rate.

## LOGISTICS AND PLANNING

Begin by uploading the MRI for selection of the size-matched meniscus allograft. Next, tentatively choose an OR date at least three (3) weeks later. Insurance approval will need to be secured before surgery. Further, ensure that a post-operative brace is available in operating room.

### TIP:

It is recommended to encourage the patient to schedule his/her first physical therapy (PT) visit a few days after surgery.

# OR EQUIPMENT LIST

This list is provided in the order that items are used during the case.

## ***For assessment and preparation of deficient meniscus and tibial attachment sites***

- ▶ Standard arthroscopy equipment – camera, pump, shaver motor, suction
- ▶ Multiple arthroscopic biters, including the following:
  - Straight – Arthrex Medium Punch Tip (AR-12300)
  - 90 degree – Arthrex Rotary Punch Tips, right and left (AR-12920, AR-12930)
  - Backwards – Arthrex Reverse Punch Tip (AR-12530)
- ▶ Arthroscopic shaver (large size to minimize clogging)
- ▶ Angled curettes

## ***For preparation of allograft meniscus***

- ▶ Scalpel with small curved cutting edge – #15 blade
- ▶ Scissors for thick tissue – curved Mayo scissors
- ▶ Scissors for delicate tissue – curved Metzenbaum scissors
- ▶ Non-absorbable suture (two) – Arthrex #2 FiberWire with Tapered Needle (AR-7200)
- ▶ Monofilament absorbable suture with needle (one) – #0 polydioxanone (PDS) or polyglyconate (Maxon)

## ***For introduction of allograft meniscus into the knee***

- ▶ Root repair system or other rigid targeting guide – Meniscal Repair and Resection Set (AR-4555S)
- ▶ 2.4 mm drill or guide pin – Arthrex Drill Tip Guide Pin, 2.4 mm (AR-1250L)
- ▶ Suture passing device (two) – Arthrex Zone Navigator (AR-7900), ZoneNavigator Anterior Cannula (AR-7905), Zone Navigator Left Middle/Posterior Cannula (AR-7910L), Zone Navigator Right Middle / Posterior Cannula (AR-7910R), Arthrex Micro SutureLasso, straight (AR-8703)
- ▶ Suture grasper – Arthrex KingFisher (AR-13970NR) or Blunt Tip Grasper (AR-12500NR)
- ▶ Suture retriever – Arthrex KingFisher (AR-13970NR) or Suture Retriever (AR-12540)
- ▶ Shuttle suture – Arthrex #2 FiberWire, 2 strands (1 blue, 1 TigerWire) (AR-7201)

***For preparation and fixation of the posterior root***

- ▶ Suture button – Arthrex ABS Button (AR-1588TB)
- ▶ Drill – Flippercutter III – AR-1204FF

***For fixation of posterior horn and posterior aspect of body***

- ▶ All-inside repair devices (two or three) – Arthrex FiberStitch Implant (AR-4570)
- ▶ Suture cutter – Arthrex Knot Pusher/Suture Cutter (AR-5815)

***For fixation of the anterior aspect of body and anterior horn***

- ▶ Monofilament absorbable suture without needle (four) – #0 PDS or Maxon

***For fixation of the anterior root***

- ▶ Punch or drill – Arthrex Punch, for 4.75 SwiveLock (AR-1927PB)
- ▶ Anchor – Arthrex BioComposite SwiveLock C, 4.75 mm, closed eyelet (AR-2324BCC)
- ▶ Suture cutter – Arthrex FiberTape Cutter (AR-13250)
- ▶ Knotless Fixation – 4.75mm Knotless SwiveLock (AR-2324KBCCT)



# MEDIAL MENISCUS ALLOGRAFT TRANSPLANTATION IN THE SETTING OF NO ASSOCIATED STRUCTURAL PATHOLOGY

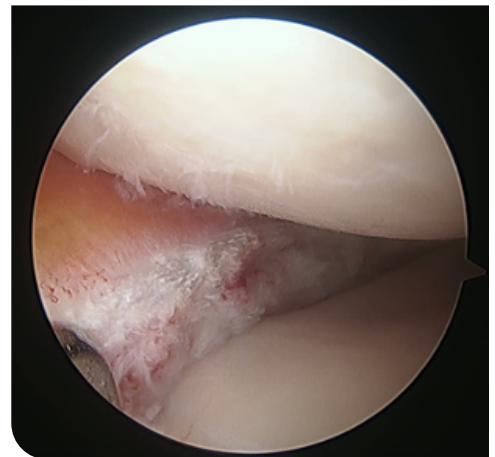
If there is a normal ACL, normal articular cartilage,  
and normal alignment, please follow the steps below.

## STEP 01

Plan incisions and arthroscopically assess the knee

## STEP 02

Prepare the native meniscus, leaving  
about a 1-mm rim peripherally.



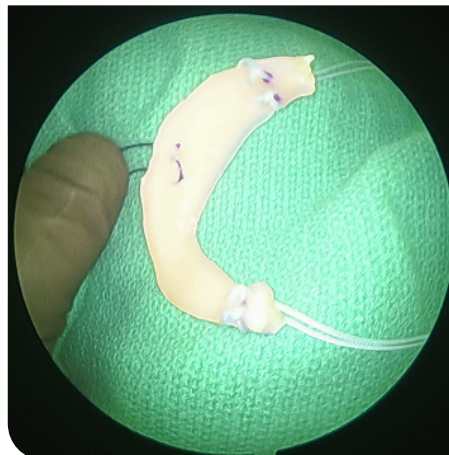
### TIP:

The anterior horn can be more easily trimmed using  
90-degree biters from the far portal or backwards (reverse)  
biters from the near portal.

---

## STEP 03

Prepare the allograft meniscus by trimming peripheral 1-mm rim and placing sutures – non-absorbable suture in each root and absorbable monofilament suture in the body.



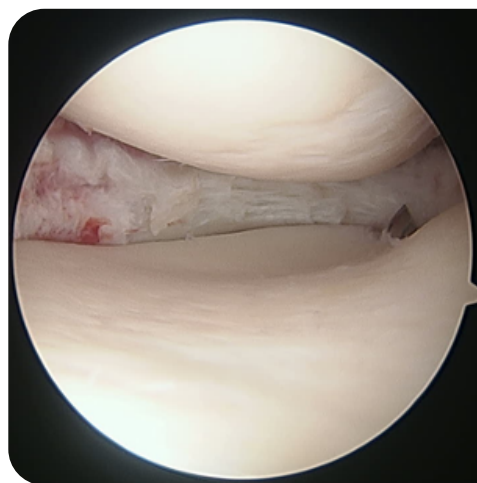
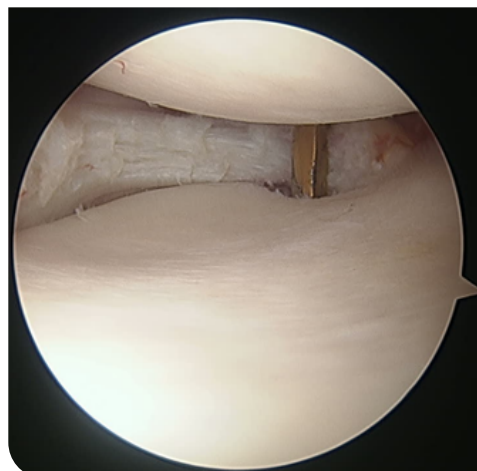
### TIP:

Lock the sutures about each root once or twice to optimize grip, but try to keep all suture material within 1 cm of each end to minimize possible abrasion of suture on the adjacent cartilage on the femoral condyle.

---

## STEP 04

Pass one loop of shuttle suture to draw in posterior horn.



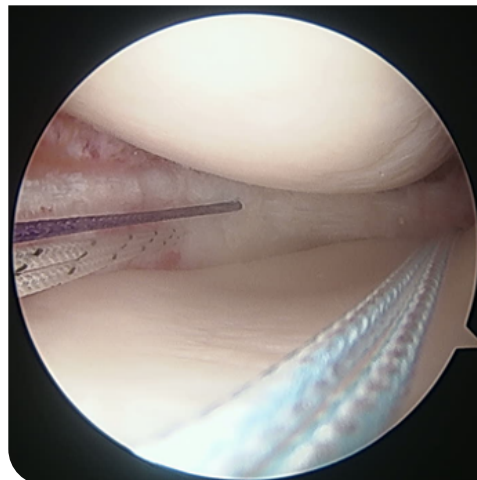
### TIP:

For the posterior horn attachment site, first use an angled curette to expose the bone. Then, place a guide pin using a low-profile tibial ACL targeting guide, choosing the portal for guide entry that minimizes torsion on the guide.

---

## STEP 05

Pass two loops of shuttle sutures to draw in body of the allograft.

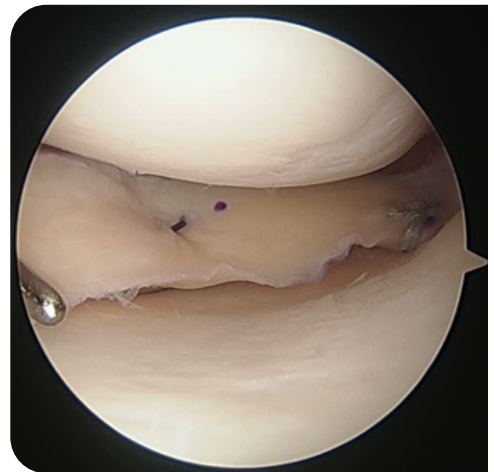
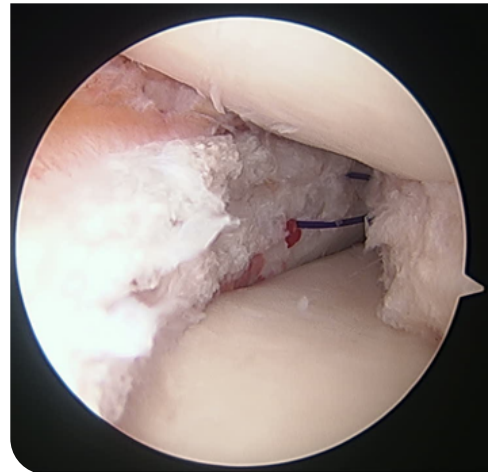


### TIP:

In order to minimize suture entanglements, retrieve the three shuttle sutures through the near portal in a set order (posterior horn, then posterior body, then anterior body).

## STEP 06

Increase portal size and draw the meniscus allograft into knee joint



### TIP:

First, pull sutures in meniscus allograft into the knee using the three suture shuttles one at a time, using the reverse order in the tip above (that is, anterior body, then posterior body, then posterior root). Then, pull these three sutures in the meniscus allograft simultaneously.

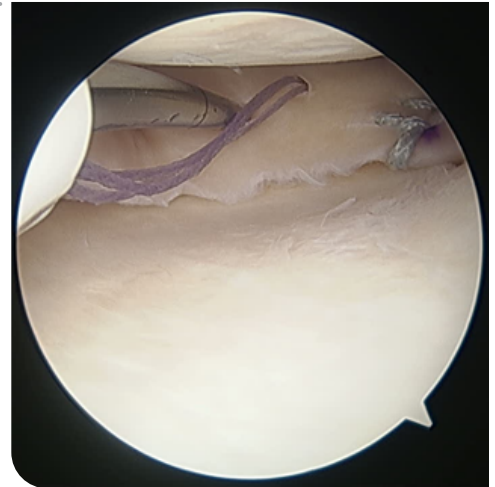
## STEP 07

Secure the meniscus.

- A. Tie posterior root suture over button  
(1 fixation point)

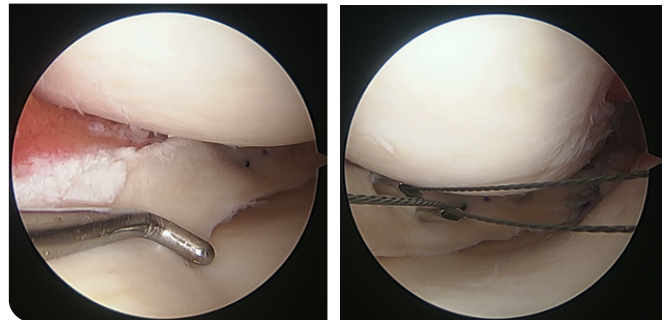
---

- B. Repair posterior horn with all-inside devices  
(2 fixation points)



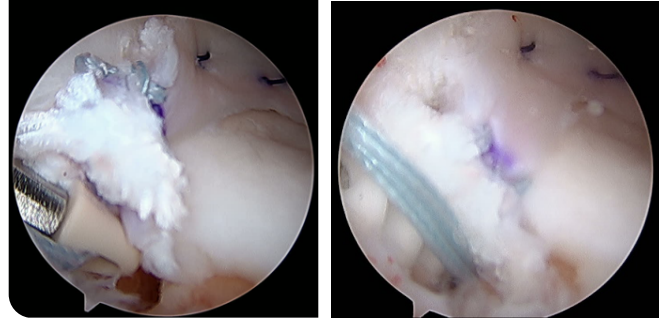
- C. Repair body using outside-in technique  
(2 fixation points)

*Note: Inside-out technique also can work nicely for body.*



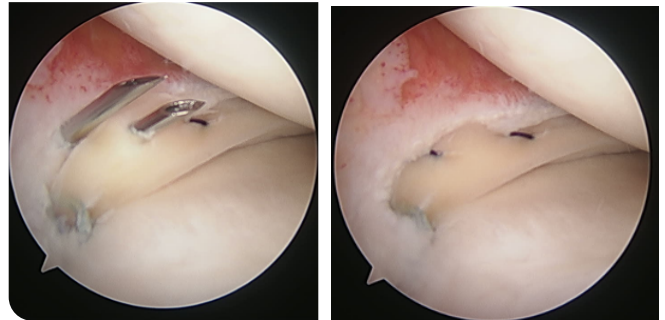
D. Place anchor for anterior horn (1 fixation point)

*Tip: For the anterior horn attachment site, first use an angled curette to expose the bone and to facilitate healing.*



E. Repair anterior horn using outside-in technique (1 fixation point)

*Tip: When the anterior horn is small, placing one limb of the suture through the allograft and one limb through the adjacent capsule works well.*



## STEP 08

Assess stability as knee extends to 0 degrees and flexes to 90 degrees

### TECHNICAL PEARLS

A few essential things to consider in order to improve success rate follow:

### TIPS:

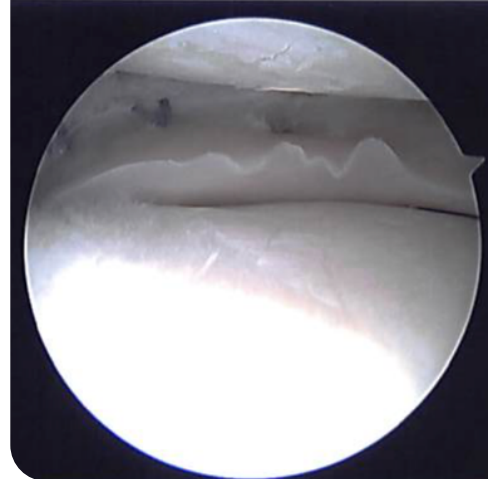
- 1: Use “nick and spread” technique for small medial incision to minimize risk of injury to saphenous nerve.
- 2: Flex knee 90 degrees and make sure that the popliteal fossa is free when using all-inside repair devices for posterior horn to minimize risk to popliteal artery and vein.
- 3: Fixation with too many fixation points may lead to “postage stamp” tearing of functional perforation – like a workbook page.
- 4: Oblique (more vertical than horizontal) suture pattern seems to work well.

# LATERAL MENISCUS VARIATION

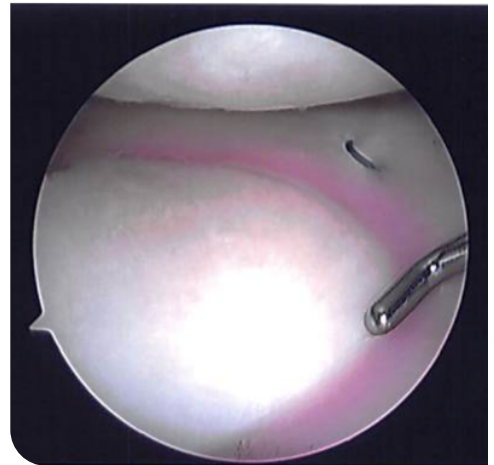
The popliteus tendon presents an additional challenge for fixation. Further, the anterior horn of the lateral meniscus is more robust and demands careful attention to anatomic positioning.

**Important:** Stay aware of popliteal artery danger and peroneal nerve danger when fixing posterior horn and body of the lateral meniscus.

.....  
Immediately medial to the popliteus tendon and hiatus, consider placing two all-inside devices.



.....  
On the other side of the tendon and hiatus, pass the body sutures immediately anterior to the LCL at the level of the joint. (The LCL can be palpated with the knee flexed 90 degrees in the figure-of-four position.)

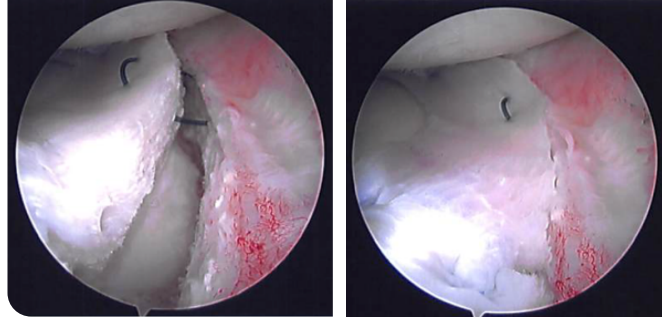




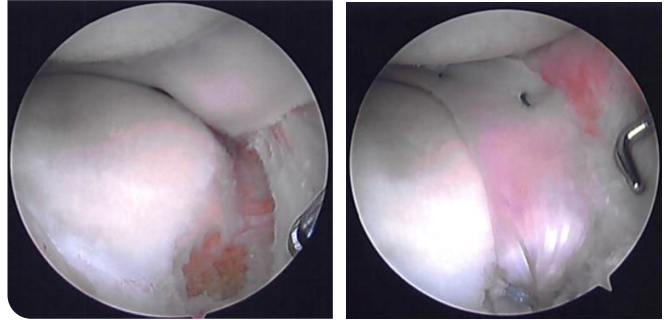
.....

Subsequently, repair lateral meniscus allograft body in similar manner (as medial in previous pages) using outside-in technique. Note that the anterior horn of a lateral meniscus is often large enough to continue oblique mattress sutures all the way to the anterior root.

.....



Place anchor for anterior horn in similar manner (as medial meniscus in previous pages). However, be sure to check position in extension and in flexion to ensure that anterior horn does not block extension.



## CONCOMITANT PROCEDURES VARIATIONS AND CONSIDERATIONS

### A. ACL intra-articular reconstruction

1. First, perform entire meniscus allograft transplantation, except fixation of anterior root.
2. Then perform entire ACL reconstruction.
3. Finally, secure anterior root of meniscus allograft with anchor.

**Rationale:** Sometimes the anchor that secures the anterior root can be coincident with part of the tibial tunnel for the ACL reconstruction. The punch and anchor of the anterior horn are fine to go into the tibial tunnel after the ACL graft is secured. However, when the order is reversed, reaming the tibial tunnel can disrupt the anchor for the anterior horn of the meniscus allograft.

### B. ACL extra-articular augmentation

1. Harvest strip of IT band for extra-articular reconstruction first.
2. Then perform meniscus allograft transplantation and ACL intra-articular reconstruction as outlined above.
3. Finally, secure IT band as part of extra-articular augmentation.

**Rationale:** Sometimes, part of the lateral meniscus allograft transplantation will involve securing the body of the meniscus about the IT band region used for extra-articular augmentation. The extra-articular augmentation should be more superficial than the lateral meniscus allograft sutures about the lateral capsule.

#### TIP:

In these cases, consider one longitudinal incision that allows easy access to tibial tunnel, femoral tunnel, IT band, and meniscus fixation points rather than 5 or 6 small incisions.

### C. Cartilage repair

1. Perform entire meniscus allograft transplantation except fixation of anterior root.
2. Then perform entire cartilage repair. (Be careful with extreme knee flexion as this can challenge the posterior root and posterior horn repair.)
3. Check posterior root and posterior horn repair. Re-tighten posterior root and re-repair posterior horn if needed.
4. Finally, secure anterior root with anchor.

**Rationale:** Flexion is often needed to access cartilage defects of the femoral condyle for fresh osteochondral allograft transplantation and autologous chondrocyte implantation. This flexion may challenge the repair of posterior horn and root of the meniscus allograft transplantation.

### D. Osteotomy

1. Perform entire osteotomy, staying extra-articular.
2. Then, perform arthroscopic meniscus allograft transplantation.

**Rationale:** Extra-articular osteotomy (for example, a high tibial or a distal femoral osteotomy) can be performed without violating the knee capsule and without eliminating the ability to retain fluid for arthroscopic visualization. The subsequent meniscus allograft transplantation can then be performed in the usual manner. Typically, the implants and hardware from these osteotomies can be easily avoided while securing the posterior root and anterior root of the meniscus allograft.

# POST-OP

## POST-OPERATIVE REHABILITATION

The first six (6) weeks are characterized by using crutches and wearing a brace as well as by observing motion limits and weight bearing precautions. The weight bearing precautions (and associated crutches) allow the anterior root and posterior root time to heal to bone. The flexion limits allow the posterior root and posterior horn time to heal before being challenged. The brace minimizes toggle on the knee and protects the knee in case of fall.

At the end of 12 weeks, motion should be normal. At 18 weeks, if the patient has normal motion, near normal strength (more than 90% of the contralateral side), and the ability to perform sport-specific activities without pain, then the patient may consider return to sports. Physical therapy and rehabilitation typically last about 18 weeks. However, the rehabilitation should be individualized.

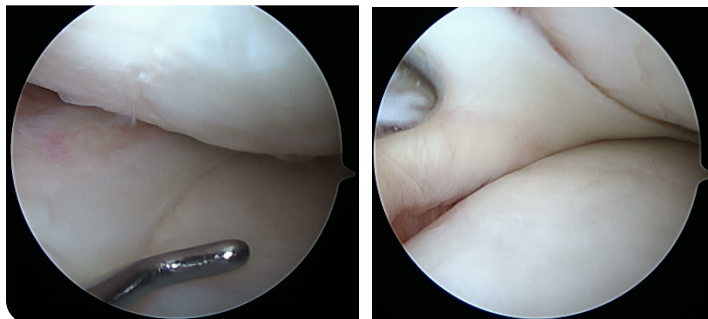
## RETURN TO PLAY CONSIDERATIONS

There are many benefits of sports participation, including but not limited to leadership, teamwork, and fitness. At the same time, there are also risks of sports participation; namely, returning to a meniscus deficient state. It is good to keep in mind that transplanted tissue may survive sports after this type of surgery.

---

## STEP 01

Assess the structure (with an MRI and “second-look” arthroscopy) whenever appropriate.



## STEP 02

Assess function and patient-oriented outcomes.

# ORDERING INFORMATION

PRODUCT DESCRIPTION	ITEM NUMBER
JRF Medial Meniscus w/ Bone Block, Right	28225001
JRF Medial Meniscus w/ Bone Block, Left	28225002
JRF Lateral Meniscus w/ Bone Block, Right	28325001
JRF Lateral Meniscus w/ Bone Block, Left	28325002
Arthrex Medium Punch Tip	AR-12300
Arthrex Rotary Punch Tips, right and left	AR-12920, AR-12930
Arthrex Reverse Punch Tip	AR-12530
Arthrex #2 FiberWire with Tapered Needle	AR-7200
Meniscal Repair and Resection Set	AR-4555S
Arthrex Drill Tip Guide Pin, 2.4 mm	AR-1250L
Arthrex Zone Navigator	AR-7900
Zone Navigator Anterior Cannula	AR-7905
Zone Navigator Left Middle/Posterior Cannula	AR-7910L
Navigator Right Middle / Posterior Cannula	AR-7910R
Arthrex Micro SutureLasso, straight	AR-8703
Arthrex KingFisher	AR-13970NR
Blunt Tip Grasper	AR-12500NR
Arthrex KingFisher	AR-13970NR
Suture Retriever	AR-12540
Arthrex #2 FiberWire, 2 strands (1 blue, 1 TigerWire)	AR-7201
Arthrex ABS Button	AR-1588TB
Flipcutter III	AR-1204FF
Arthrex FiberStitch Implant	AR-4570
Arthrex Knot Pusher/Suture Cutter	AR-5815
Arthrex Punch, for 4.75 SwiveLock	AR-1927PB
Arthrex BioComposite SwiveLock C, 4.75 mm, closed eyelet	AR-2324BCC
Arthrex FiberTape Cutter	AR-13250
4.75mm Knotless SwiveLock	AR-2324KBCCT