

Evaluation of FastThread™ BioComposite Interference Screws in a Preclinical Canine Model

Arthrex Research and Development

James L. Cook, DVM, PhD; Chantelle Bozynski, DVM; and Keiichi Kuroki, DVM, PhD from the University of Missouri

Objective

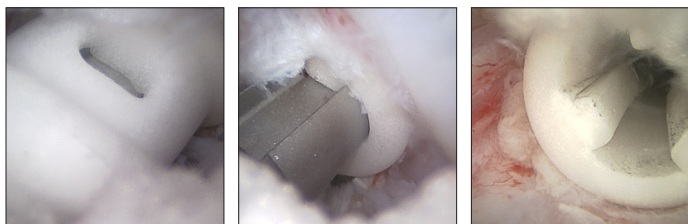
Bioabsorbable interference screw fixation of grafts is currently considered the standard of care for ACL reconstruction. Fixation, integration, and absorption properties of bioabsorbable interference screws have been improved when “vents” have been incorporated into the screw design. The objective of this study was to assess the early histological results of the next-generation FastThread BioComposite screw in a preclinical canine ACL fixation model. This screw is designed with a larger thread pitch to facilitate insertion and vents to reduce the amount of foreign material in the tunnel.

Methods and Materials

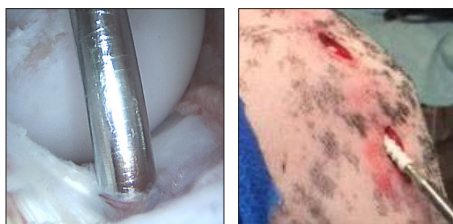
With Animal Care and Use Committee (ACUC) approval, adult purpose-bred hounds underwent aseptic surgery to perform arthroscopy-assisted vented FastThread interference screw (N=7) implantation at femoral and tibial ACL footprints (Fig. 1). Sham (drilled, tapped, no screw inserted) (N=3) and no-surgery (N=2) procedures were included as controls. Knees were assessed clinically based on maintenance of joint function, and at 16 weeks postimplantation using arthroscopic, gross, and histologic evaluations to determine maintenance of screw position and integrity, as well as cellular responses, screw-bone interface appearance, and bone ingrowth into the implants.

Figure 1: Surgical Implantation

Femoral



Tibial



Results

All dogs maintained normal clinical function after recovery with no complications or impairments noted. Knee range of motion was within normal limits in all dogs at the end of the study period. No implants migrated and no inflammatory reactions or other untoward responses were noted in any joint based on clinical, arthroscopic, gross, and histologic assessments.

Figure 2: Arthroscopic assessments at 16 weeks postimplantation documented maintenance of vented FastThread interference screws' integrity and position for all implants.

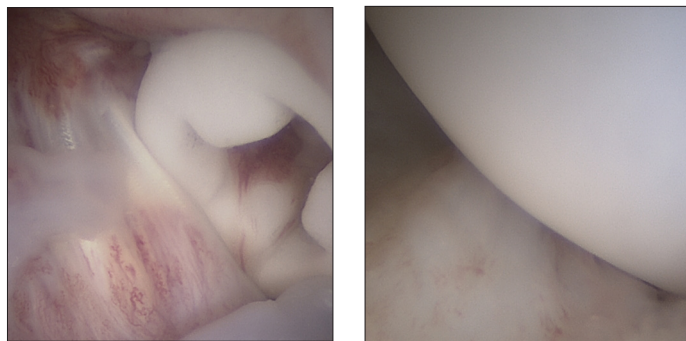


Figure 3: Gross assessments at 16 weeks postimplantation documented maintenance of vented FastThread interference screws' integrity and position for all implants with evidence for excellent implant-bone interfaces of bone and connective tissue in the cannulation channels.

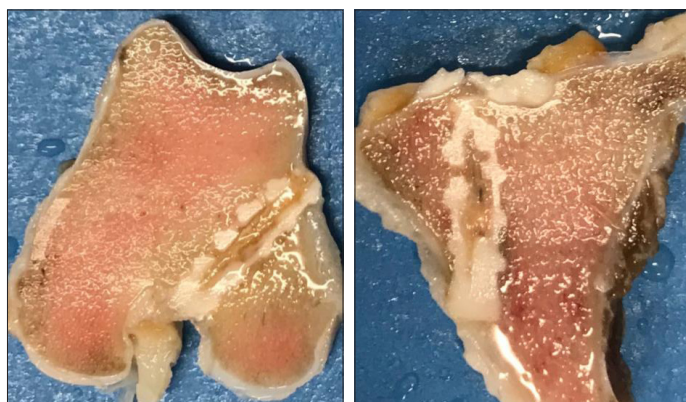
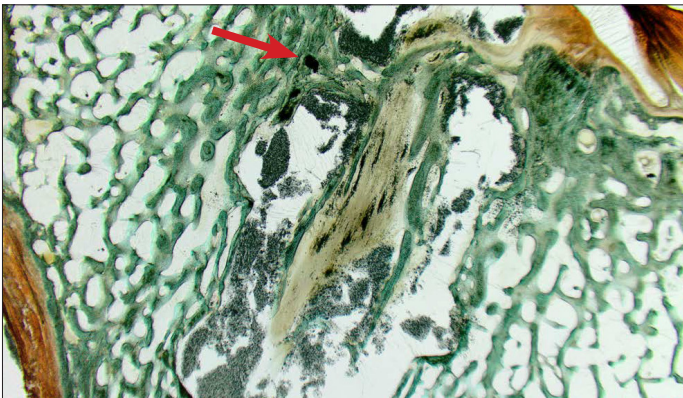
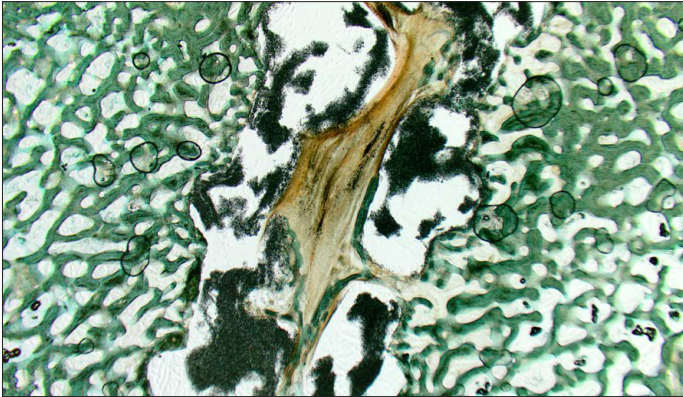


Figure 4: Histologic assessments at 16 weeks postimplantation documented consistent findings for all vented FastThread™ BioComposite interference screws, showing the screw closely surrounded by dense, variably thickened, anastomosing bone trabeculae and minimal to moderate quantities of connective tissue intercepted by spindle cells and small to moderate numbers of round cells. The cannulation channels of the screws were infiltrated by small to moderate quantities of connective tissue and moderate quantities of bone trabeculae. (Sham sites showed dense, variably thickened, anastomosing bone trabeculae with no to minimal connective tissue consistent with remodeling bone; control sites showed normal trabecular and subchondral bone.)



Clinical Relevance

In this preclinical canine ACL fixation model, vented FastThread BioComposite interference screws maintained integrity and position, produced no untoward responses in the knee, and were associated with excellent implant-bone interfaces and consistent bone ingrowth (red arrow) into the cannulation channel for all implants at both femoral and tibial insertion sites at 4 months postsurgery. Based on these data, FastThread interference screws appear to be appropriate for clinical use.