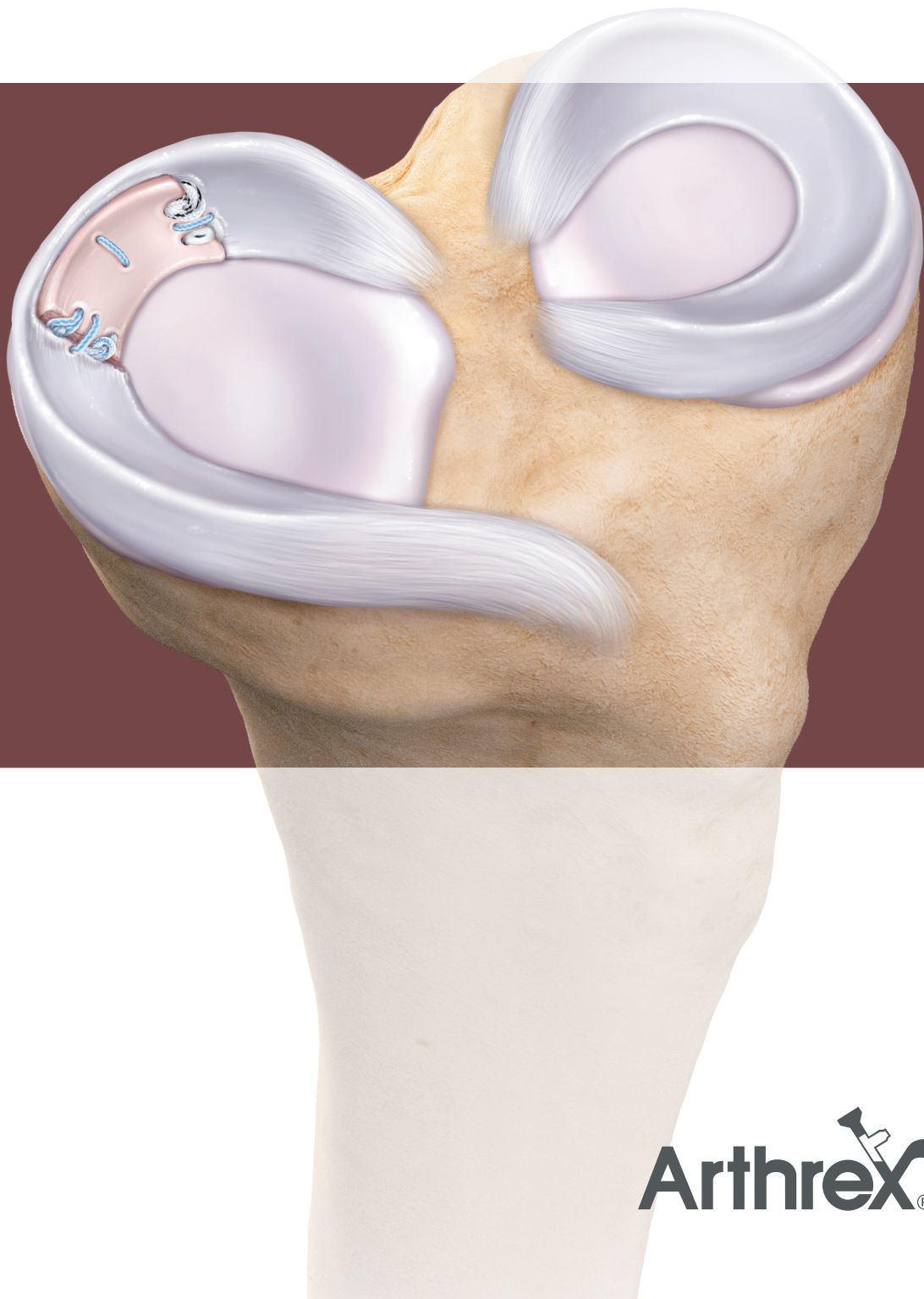


# Segmental Meniscus Allograft Transplantation

Surgical Technique



---

# Segmental Meniscus Allograft Transplantation Technique

By Matthew T. Provencher, MD, CAPT (Ret)

---

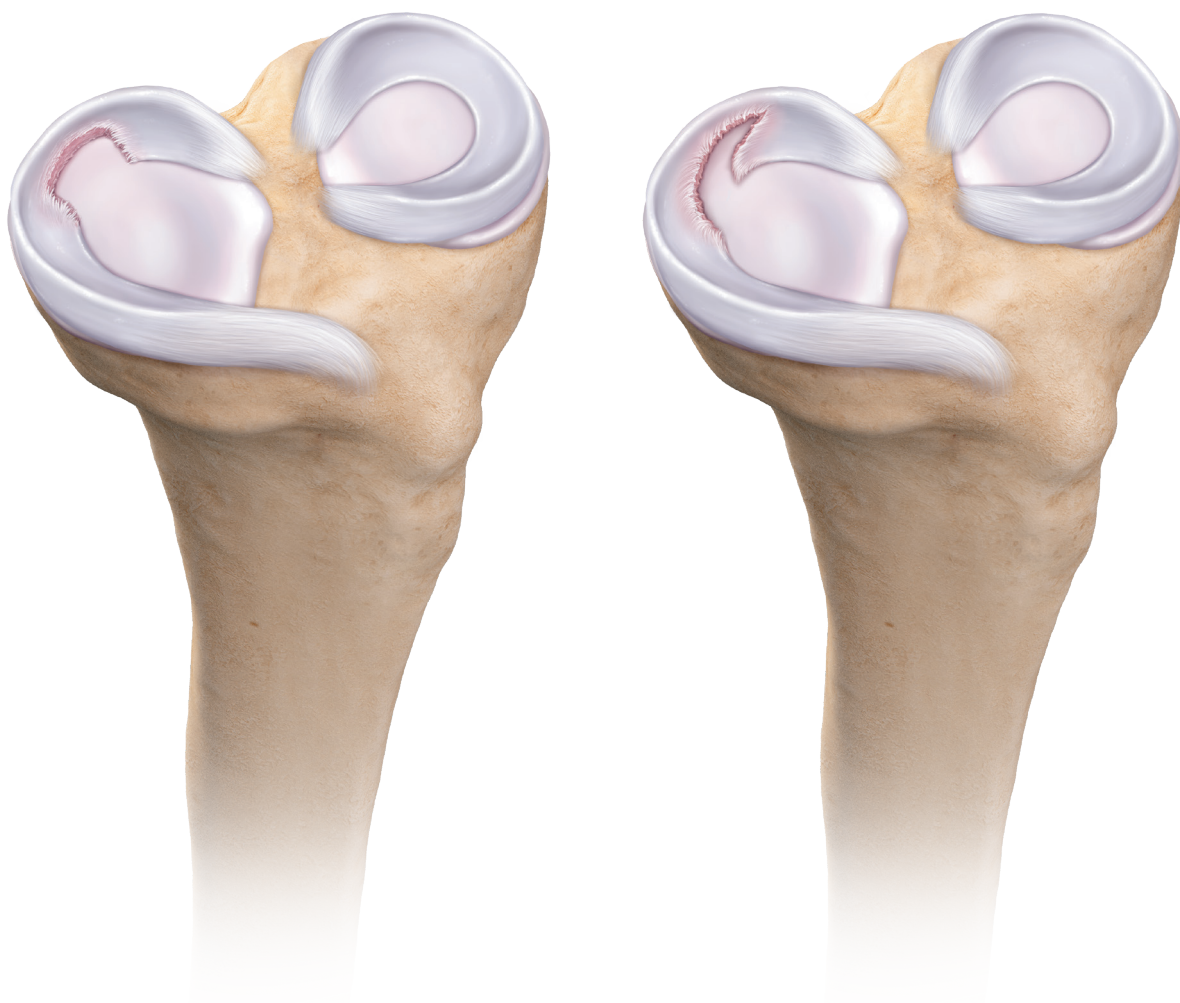Segmental meniscus transplantation serves as a robust repair option for restoring meniscal function and kinematics in patients with partial meniscal deficiency. Many of the meniscal deficiencies we encounter are only partial or segmental in nature; a segmental meniscal allograft addresses this pathology while maintaining knee kinematics, restoring biology, and maximizing preservation of native meniscal tissue.<sup>1-3</sup> This is especially helpful for the common areas of meniscal deficiency, particularly the posterior horn, middle horn, or both.

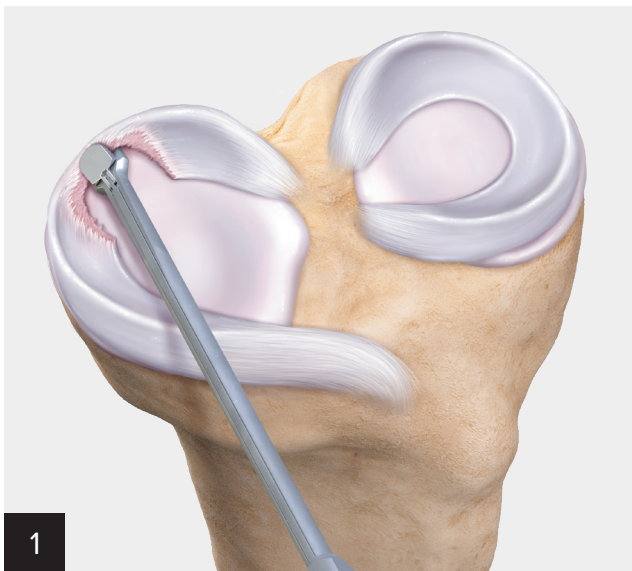
Using meticulously designed cutting and measuring instruments, surgeons can identify and outline the extent of damage to the meniscus and precisely trim the allograft meniscal segment to be transplanted.

This technique also uses suturing devices, including all-inside and inside-out devices, that facilitate restoration of meniscal kinematics and help to stabilize

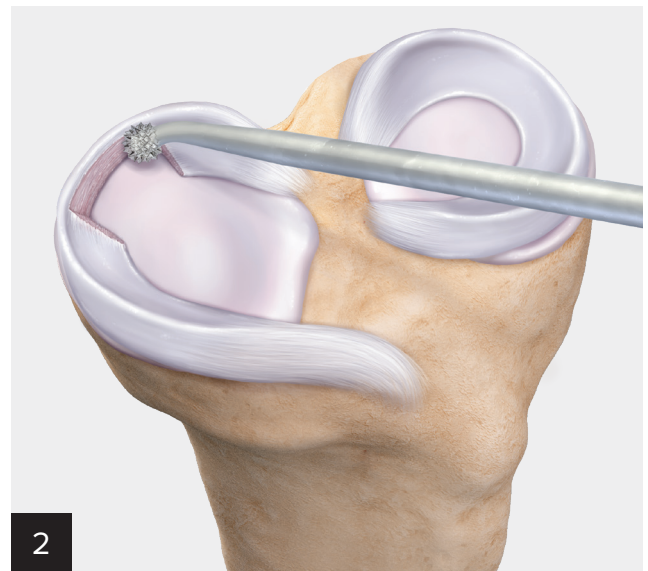the meniscal segment. Multiple size and measurement options and precise trimming options allow for excellent matching of the allograft segmental meniscus. In addition, size-matching is not necessary for smaller segmental defects (those measuring less than 1 cm up to 2.5 cm). Off-the-shelf meniscus allograft tissue may be used in these cases.

In summary, segmental meniscus transplantation provides an acceptable alternative for patients who have undergone meniscectomy and for whom function and circumferential mechanical aspects of a deficient meniscus are present. Ultimately, by restoring the tibiofemoral contact pressures in the knee, it may be possible to improve knee stability and prevent the onset of cartilage degeneration commonly observed following meniscectomy procedures.<sup>1,4</sup>

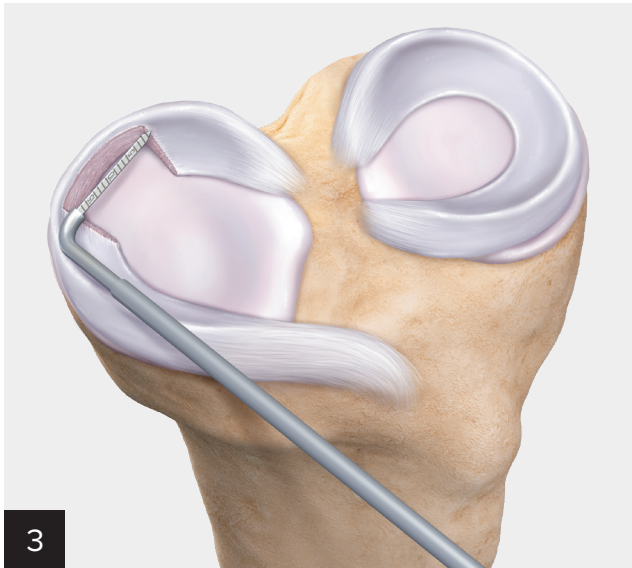




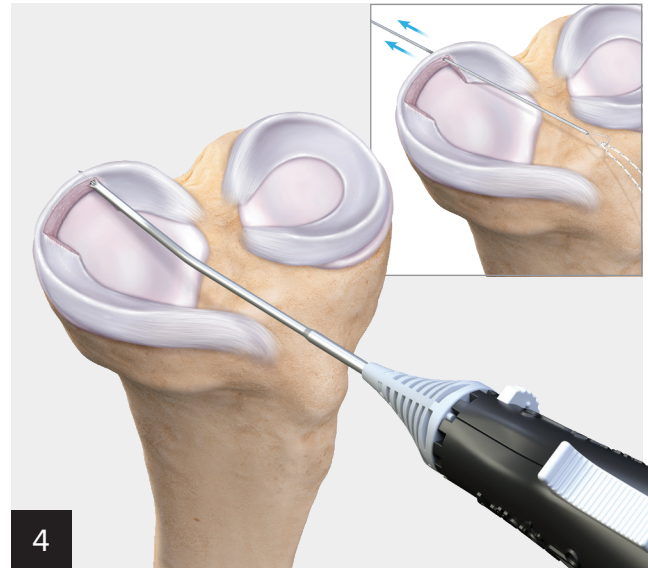Use the MegaBiter™ tool to create stable borders on the segmental defect; take care to maintain capsular rim.



Use a rasp to stimulate bleeding from the native capsular attachment.

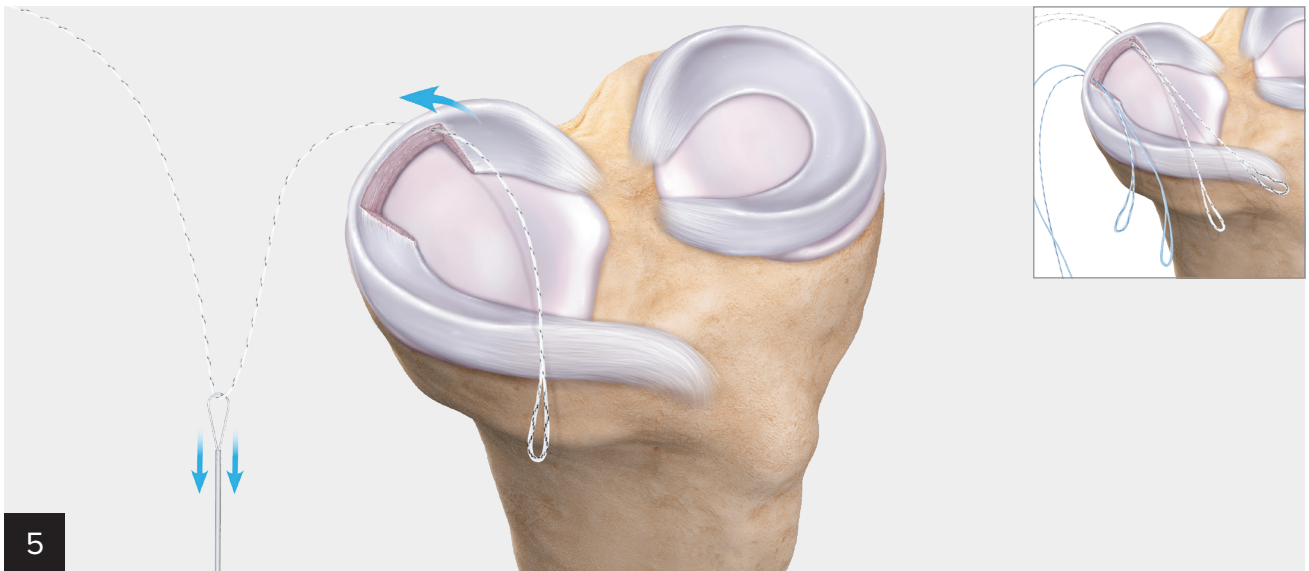


Measure the inner and outer lengths of the defect to account for the native curvature of the meniscus and defect. In addition, measure the depth of the defect at the anterior and posterior aspects.

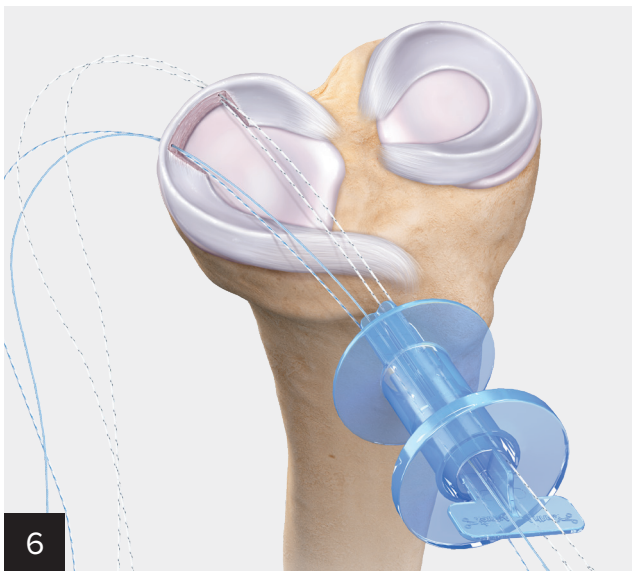


Using an inside-out approach, use the ZoneNavigator™ device to approximate each quadrant of the defect.

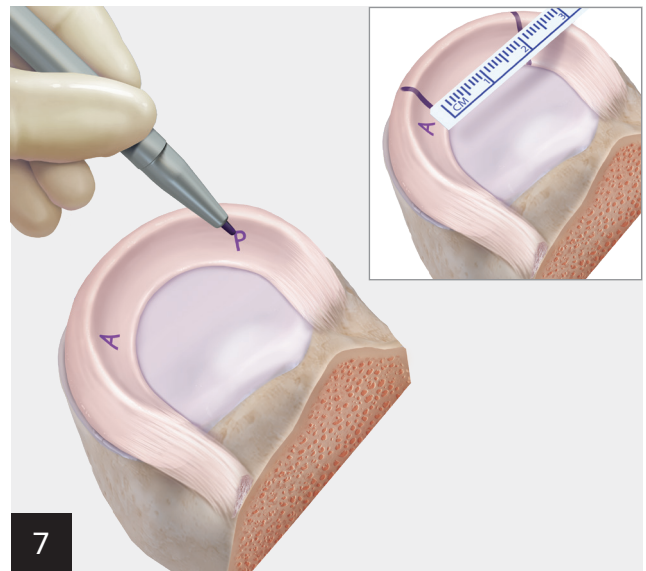




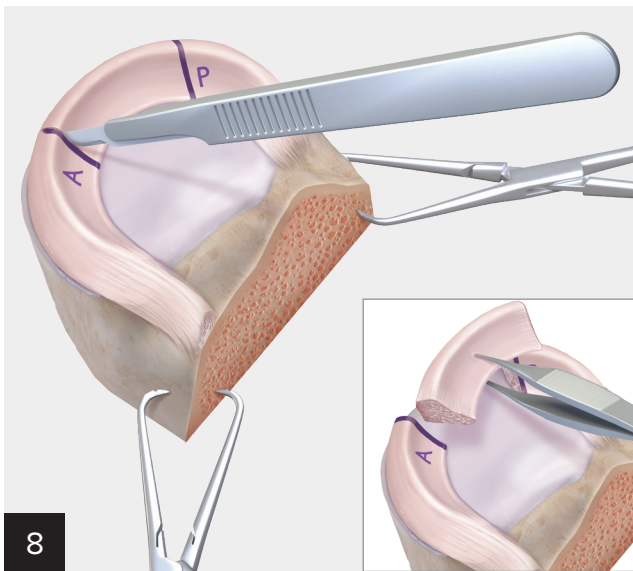
Advance the needle with 2-0 TigerLink™ SutureTape through the nitinol loop. Repeat for the posterior inferior quadrant. Repeat using FiberLink™ SutureTape suture for the anterior superior and inferior quadrants.



Insert the 12 mm PassPort Button™ cannula with four-quadrant divider to aid in suture management.

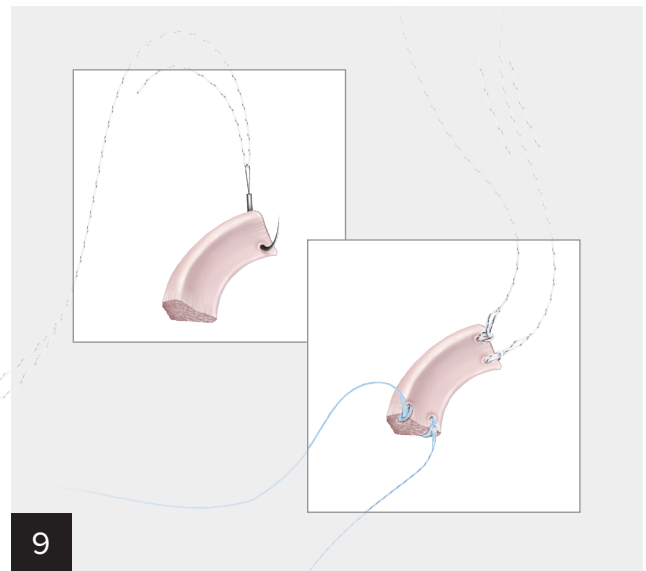


Label the anterior and posterior horns of the allograft. Mark the measurements of the defect on the allograft, taking care to measure both the inner and outer lengths of the segment.



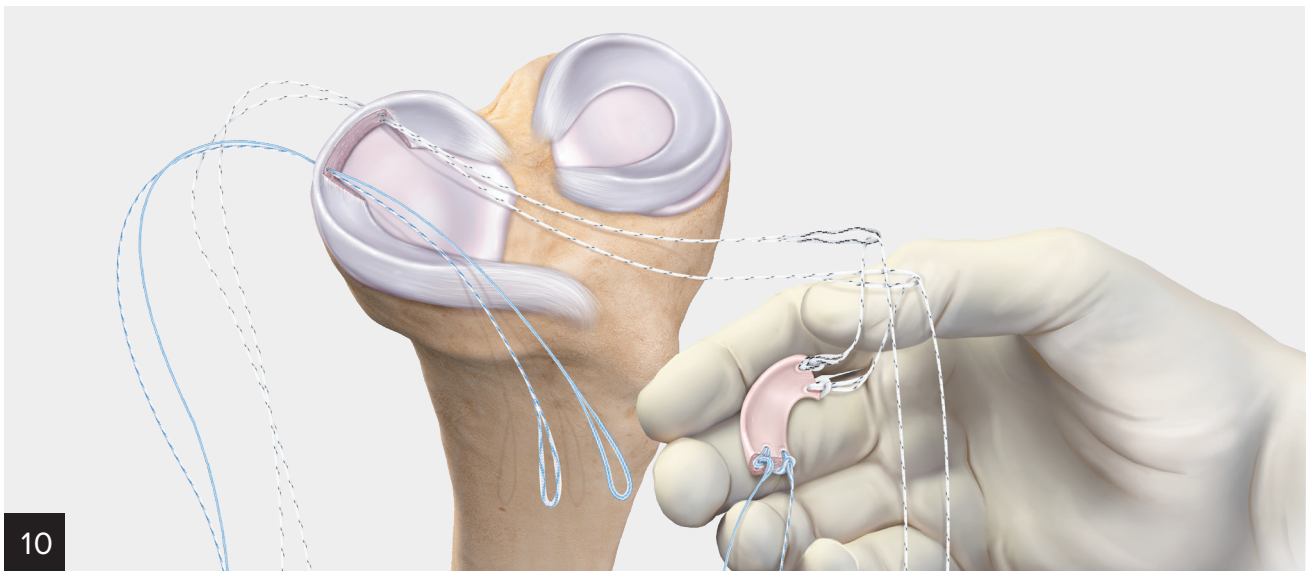
8

Cut allograft to desired length. **Technique pearl: Cut allograft 1 mm shorter than the defect measures to ensure graft fit.**



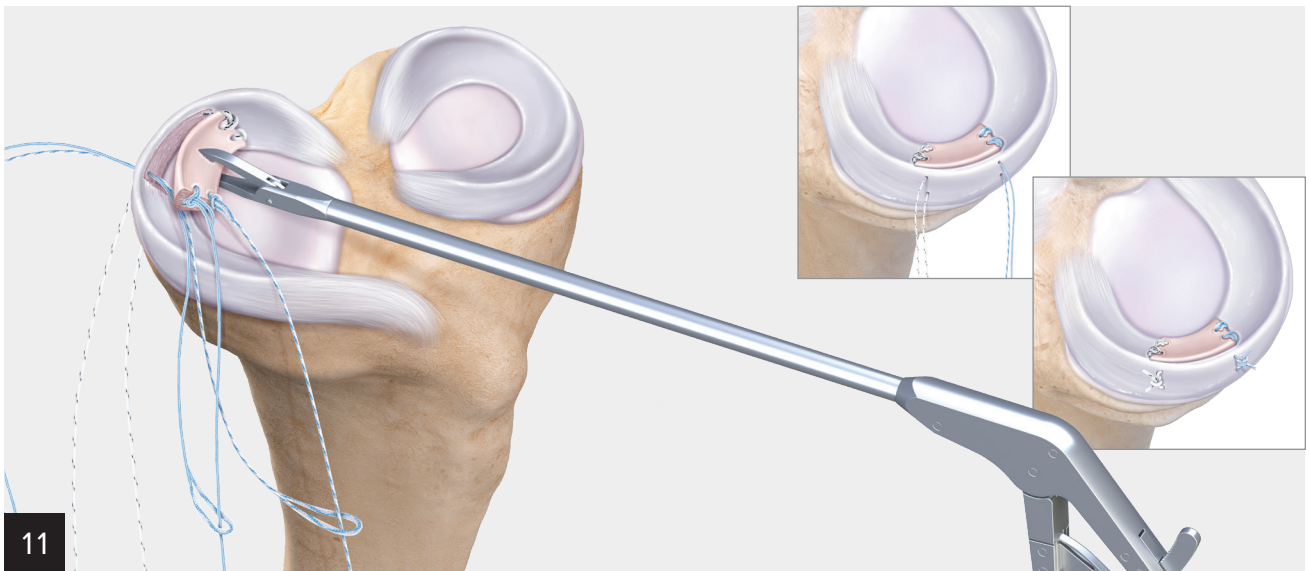
9

On the donor graft, use a cutting needle with attached nitinol loop to pass FiberLink™ and TigerLink™ SutureTape sutures that correspond to the SutureTape sutures that have been passed in the recipient site. Create a cinch configuration on each suture.

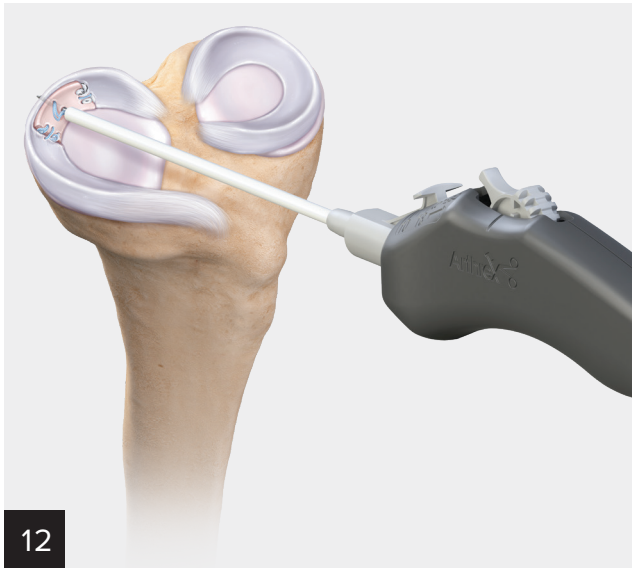


10

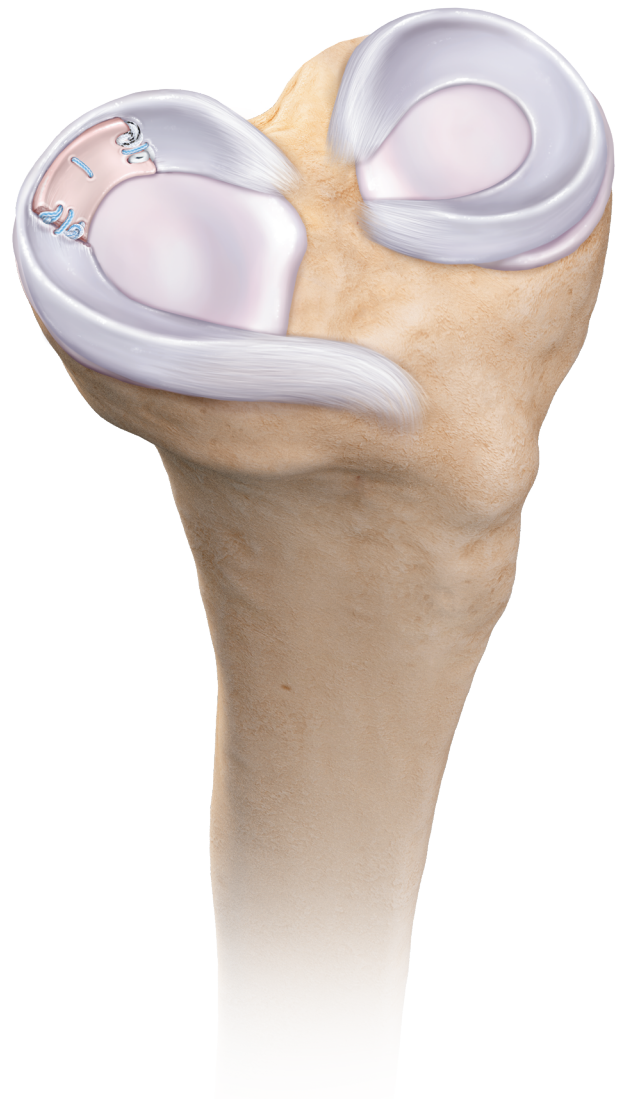While maintaining good suture management, remove divider and PassPort Button™ cannula, then assemble and pass posterior links.



At this step, the posterior graft has been delivered. Assemble and pass the anterior links. Advance the segmental graft to the defect using the KingFisher® grasper while tensioning suture tails. To complete primary fixation, tie sutures over the capsule.



**Optional:** Complete fixation using FiberStitch™ implants as necessary along rim of meniscal segment.



## Ordering Information

Product Description	JRF Ortho Part Number	LifeNet Health Part Number
Lateral Meniscus, right	28325001	<b>FMN RL</b>
Lateral Meniscus, left	28325002	<b>FMN LL</b>
Medial Meniscus, right	28225001	<b>FMN RM</b>
Medial Meniscus, left	28225002	<b>FMN LM</b>

### Accessories and Supportive Products

Product Description	Item Number
MegaBiter™ Resector, straight tip, 5.5 mm × 2.5 mm	AR-41006
Arthroscopic Measurement Probe, 60°, 220 mm	AR-4070-01
ZoneNavigator™ System Anterior Cannula	AR-7905
ZoneNavigator System Cannula, left posterior	AR-7910L
ZoneNavigator System Cannula, right posterior	AR-7910R
2-0 Mini SutureTape Meniscus Repair Needles	AR-7523
Arthroscopic Knot Pusher, closed end	AR-1305
FiberStitch™ Implant, curved, w/ two polyester implants and 2-0 FiberWire® suture	AR-4570
FiberStitch Implant, 12° reverse curve	AR-4570R
FiberStitch Implant, 24° up curve	AR-4570-24
FiberStitch Implant, straight	AR-4570S
FiberLink™ SutureTape Suture, 0.9 mm, white/black	AR-7559
TigerLink™ SutureTape Suture, 0.9 mm, white/black	AR-7559T
0 FiberLink Suture, FiberWire suture w/ 1.5 in closed loop at one end (blue)	AR-7258
0 TigerLink Suture, TigerWire® suture w/ 1.5 in closed loop at one end (white/black)	AR-7258T

Products advertised in this brochure/surgical technique guide may not be available in all countries. For information on availability, please contact Arthrex Customer Service or your local Arthrex representative.

## References

- Nyland J, Campbell K, Kalloub A, Strauss EJ, Kuban K, Caborn DNM. Medial meniscus grafting restores normal tibiofemoral contact pressures. *Arch Orthop Trauma Surg.* 2018;138(3):361-367. doi:10.1007/s00402-017-2849-x
- Seiter MN, Haber DB, Ruzbarsky JJ, Arner JW, Peebles AM, Provencher MT. Segmental meniscus allograft transplantation. *Arthrosc Tech.* 2021;10(3):e697-e703. doi:10.1016/j.eats.2020.10.059
- Strauss E, Caborn DNM, Nyland J, Horng S, Chagnon M, Wilke D. Tissue healing following segmental meniscal allograft transplantation: a pilot study. *Knee Surg Sports Traumatol Arthrosc.* 2019;27(6):1931-1938. doi:10.1007/s00167-019-05355-z
- Roos H, Laurén M, Adalberth T, Roos EM, Jonsson K, Lohmander LS. Knee osteoarthritis after meniscectomy: prevalence of radiographic changes after twenty-one years, compared with matched controls. *Arthritis Rheumatol.* 1998;41(4):687-693. doi:10.1002/1529-0131(199804)41:4<687::AID-ART16>3.0.CO;2-2



This description of technique is provided as an educational tool and clinical aid to assist properly licensed medical professionals in the usage of specific Arthrex products. As part of this professional usage, the medical professional must use their professional judgment in making any final determinations in product usage and technique. In doing so, the medical professional should rely on their own training and experience, and should conduct a thorough review of pertinent medical literature and the product's directions for use. Postoperative management is patient-specific and dependent on the treating professional's assessment. Individual results will vary and not all patients will experience the same postoperative activity level and/or outcomes.

View U.S. patent information at [www.arthrex.com/corporate/virtual-patent-marking](http://www.arthrex.com/corporate/virtual-patent-marking)

**arthrex.com**

© 2021 Arthrex, Inc. All rights reserved. LT1-000221-en-US\_A