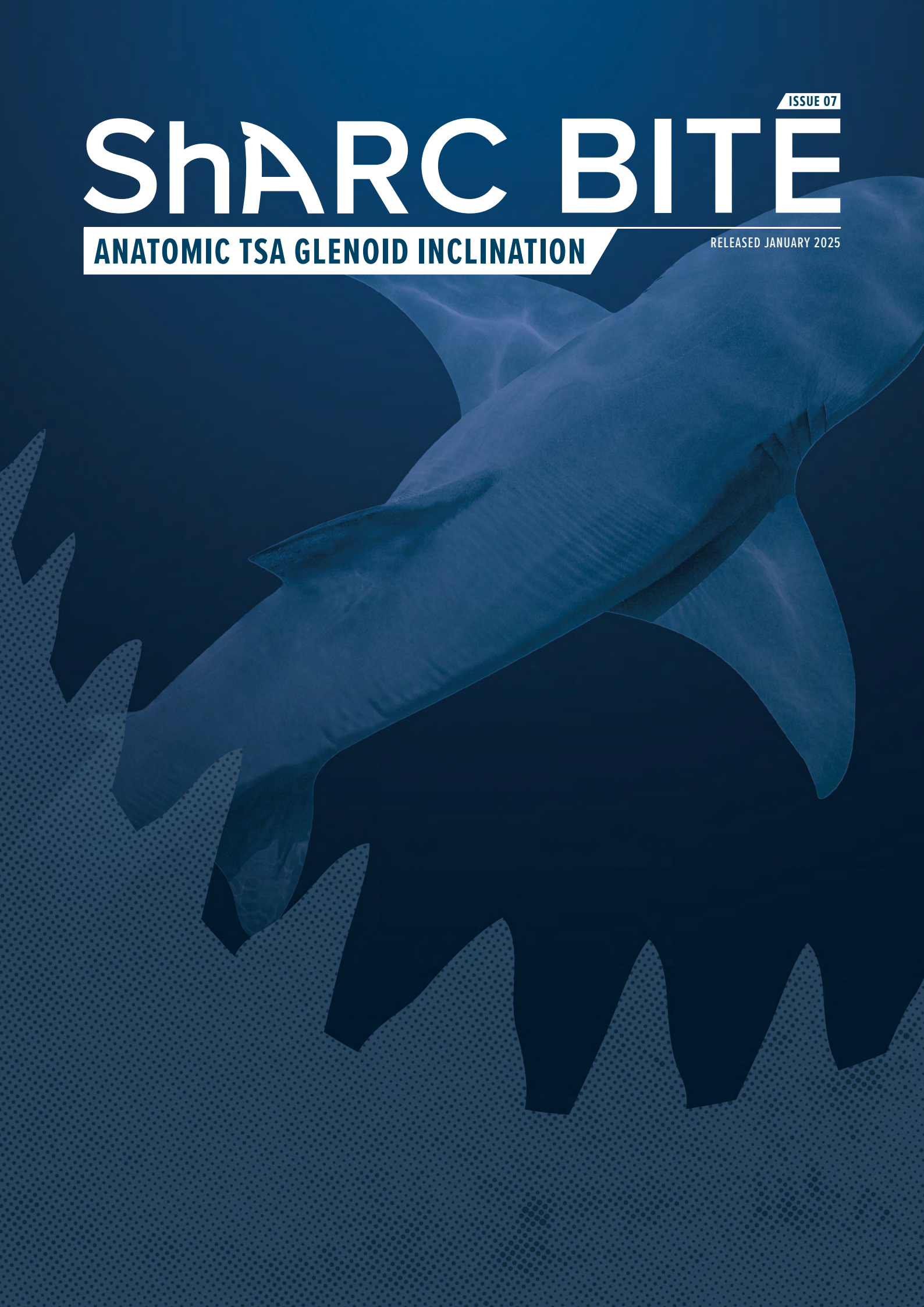

ISSUE 07

ShARC BITE

ANATOMIC TSA GLENOID INCLINATION

RELEASED JANUARY 2025



Mission Statement

The Shoulder Arthroplasty Research Committee (ShARC) is a forward-looking global collaboration among research-focused surgeons of which the primary goal is to advance patient care. The ShARC Patient Registry is utilized to conduct patient monitoring, inform evidence-based implant design, and allow for the integration of novel technologies into clinical practice. Supported by Arthrex, the ShARC will continue to have tremendous influence on the advancement of shoulder arthroplasty through innovative research and a commitment to improve patient outcomes.

ShARC Bites are developed through registry data analysis and processing of the committee's preferences, cross-referenced with available ShARC and non-ShARC publications, to provide recommendations on current techniques and implants.

Summary Recommendation

Absent deformity, most ShARC surgeons aim to match native glenoid inclination. If correcting, the majority aim for less than 5° of inferior inclination, with the goals of improving and protecting supraspinatus function and preventing proximal humeral migration. However, inferior inclination should not be achieved by excessive reaming and compromise of subchondral bone support, with nearly all surgeons stating they would not ream more than 3 mm to correct glenoid inclination.

Background

The ideal inclination for the glenoid component in anatomic shoulder arthroplasty for glenohumeral osteoarthritis has not been well defined. Finite element, cadaveric, and clinical outcome and radiographic studies have provided some insights, but the data is insufficient to establish a standardized position for all patients.

When preoperative inclination exceeds 10° but is properly corrected, it does not seem to have a major impact on the postoperative results of anatomic TSA. However, there is a notable link between postoperative inclination and Constant scores at the 2-year mark, with correction of inclination correlating to improved postoperative Constant scores.¹ These findings highlight the importance of further research to better understand and optimize inclination correction for achieving positive and lasting outcomes after anatomic TSA.

Jacxsens et al found that preoperative glenoid inclination was the sole anatomical factor affecting clinical outcomes, with increased inferior inclination associated with significantly reduced Constant scores at final follow-up.² Terrier et al used a numeric musculoskeletal model to assess the benefit of inferior inclination of the glenoid component to balance supraspinatus insufficiency, finding that it improved balance and reduced proximal humeral migration but required additional subchondral bone reaming, reducing bone support and increasing cement deformation and stress.³

Knighton et al used a cadaveric shoulder simulator to study joint contact and muscle forces with isolated changes in glenoid inclination, finding that inferior glenoid inclination reduced both compressive and superior-inferior shear forces compared to neutral inclination by up to 40%, potentially reducing the likelihood of glenoid loosening. However, the impact of corrective reaming and loss of subchondral bone to achieve that inclination was not defined.⁴ Hopkins et al performed a finite element analysis of five different glenoid component alignments to evaluate the survivability of the cement mantle surrounding the glenoid component, finding that the quality of the supporting bone stock was particularly significant to cement survivability, with a superiorly inclined glenoid component performing worst overall.⁵ Gregory et al reported that an inferiorly inclined glenoid component was associated with an increased incidence of radiolucent lines and osteolysis after total shoulder arthroplasty.⁶

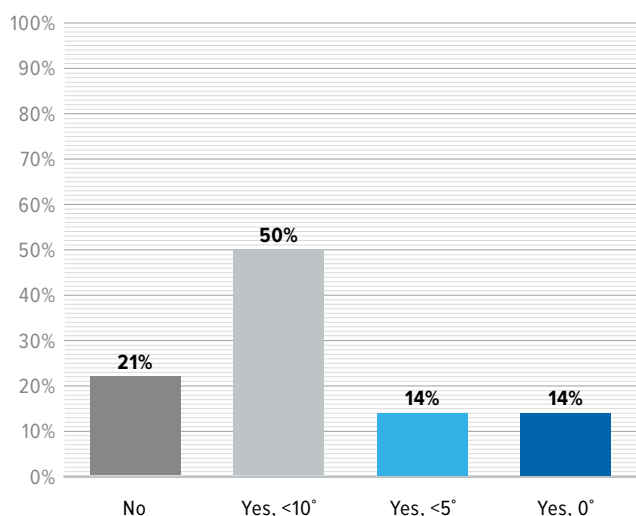
Results

Twenty-eight high-volume shoulder arthroplasty surgeons were surveyed regarding their goal and preference for glenoid component position in anatomic shoulder arthroplasty.

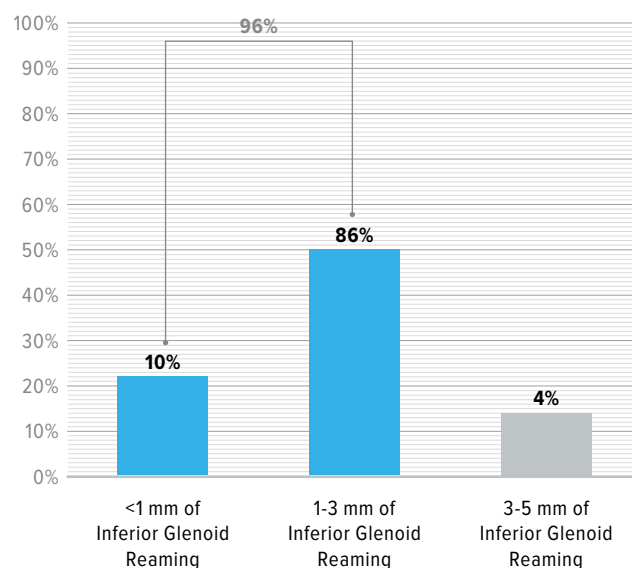
Only 21% of surgeons stated they did not have a target goal for inclination, while 50% said they aim for less than 10° of glenoid inclination. Twenty percent of surgeons indicated improved function of the rotator cuff as the primary reason for this preference, while others cited reduced shear forces and cement mantle stresses.

Ninety-six percent of surgeons reported 3 mm to be the upper limit of reaming that is acceptable to achieve this desired correction, given concerns about loss of subchondral bone support for the implant.

Do you have an absolute goal for glenoid inclination in anatomic TSA?

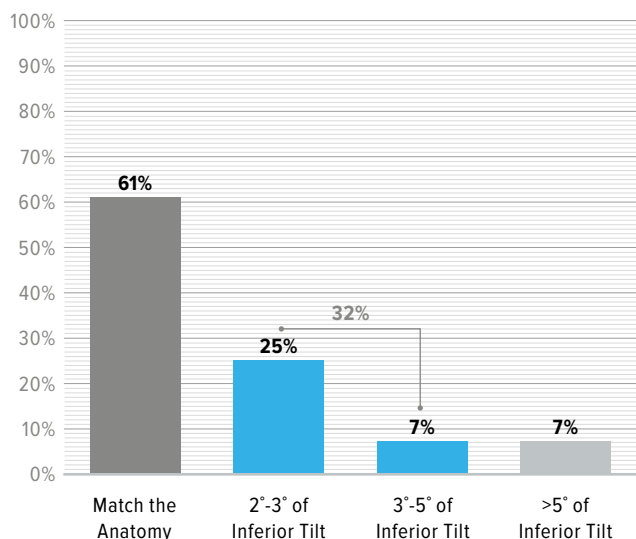


What is your upper limit of acceptable inferior glenoid reaming in anatomic TSA?



Absent deformity, 61% of surgeons aim to match the native anatomy of the glenoid, while 32% aim to introduce 2° to 5° of inferior tilt to improve rotator cuff function and prevent proximal humeral migration.

Do you have an absolute goal for inferior tilt in anatomic TSA?



References

1. Griffin JW, Denard P, Romeo A, Gobeze R, Lederman E, Werner B. Inclination correction is associated with improved clinical outcomes in anatomic total shoulder arthroplasty. *Semin Arthroplasty*. 2021;31:557-562. <https://doi.org/10.1053/j.sart.2021.03.005>
2. Jacxsens M, Henninger H, Van Tongel A, De Wilde L. Serial 3D CT analysis of humeral head alignment in relation to glenoid correction and outcomes after total shoulder arthroplasty. *JSES International*. 2023; 7:485-492.
3. Terrier A, Merlini F, Pioletti DP, Farron A. Total shoulder arthroplasty: Downward inclination of the glenoid component to balance supraspinatus deficiency. *Journal Shoulder Elbow Surgery*. 2009; 18:360-365.
4. Knighton TW, Chalmers PN, Sulkar HJ, Aliaj K, Tashjian RZ, Henninger HB. Anatomic total shoulder glenoid component inclination affects glenohumeral kinetics during abduction: a cadaveric study. *Journal Shoulder Elbow Surgery*. 2022; 31:2023-2033.
5. Hopkins AR, Hansen UN, Amis AA, Emery R. The effects of glenoid component alignment variations on cement mantle stresses in total shoulder arthroplasty. *Journal Shoulder Elbow Surgery*. 2004; 13:668-675.
6. Gregory TM, Sankey A, Augereau B, Vandenbussche E, Amis A, Emery R, Hansen U. Accuracy of Glenoid Component Placement in Total Shoulder Arthroplasty and Its Effect on Clinical and Radiological Outcome in a Retrospective, Longitudinal, Monocentric Open Study. *PLOS One*. 2013; 8:75791-75796.



View the ShARC
Publication List

ShARC
Shoulder Arthroplasty Research Committee

